

# Robot-assisted thoracoscopic repair of a late-onset Bochdalek hernia: a case report

Mario Lima, Niel Di Salvo, Sara Ugolini, Michele Libri, Giovanni Ruggeri

*Sant'Orsola-Malpighi Hospital; Department of Pediatric Surgery, University of Bologna, Bologna, Italy*

## Abstract

Bochdalek hernia (BH) is a major malformation that consists of a postero-lateral diaphragmatic defect through which abdominal contents can migrate into the thorax. It is most commonly a neonatal pathology associated with significant morbidity and mortality. Rarely, this type of congenital diaphragmatic hernia (CDH) presents later in life, some even in adulthood. Indications for surgery are not clear even though the majority of authors, being aware of the possible severe complications, recommend surgical correction in all cases. Many surgical approaches have been tried for this pathology, both open (laparotomic or thoracotomic) and minimally invasive (laparoscopic or thoracoscopic). We report a case of a late-onset BH corrected with a robot-assisted thoracoscopic procedure. The use of robotic technology for CDH has never been described to date.

## Introduction

Bochdalek hernia (BH) is the most frequent type of congenital diaphragmatic hernia (CDH).<sup>1</sup> It is defined as a postero-lateral

defect of the diaphragm (more often in the left side) through which abdominal contents can migrate into the thorax. Being a major malformation, CDHs become evident in the first hours of life, through symptoms related to respiratory distress. Rarely, these hernias present later in life, some even in adulthood. Many surgical approaches have been tried for this pathology, both open (laparotomy or thoracotomy) and minimally invasive (laparoscopic or thoracoscopic). We report a case of a late-onset BH corrected with a robot-assisted thoracoscopic procedure.

## Case Report

In this paper we present the case of a 27-year-old male patient who was referred to our center being specialized in surgical correction of congenital thoracic anomalies. As a matter of fact in the last 10 years we have gained a certain experience in the thoracoscopic correction of CDH. His detailed medical history revealed three episodes of pneumonia during childhood. He had also suffered from chronic back pain in the last 5 years; the pain was localized in the dorso-lumbar tract of the spine (especially between D11 and L2 vertebrae). For this reason his family doctor ordered a Magnetic Resonance Imaging (MRI) in the suspicion of a discal hernia. The MRI did not confirm such suspicion but detected the presence of fat tissue in the left hemithorax, between the diaphragmatic dome and the lung. He then underwent a computed tomography (CT) scan that affirmed the diagnosis of left postero-lateral diaphragmatic hernia – BH – with herniation of omentum (Figure 1).

We then proposed to the patient a robot-assisted thoracoscopic repair of the hernia. One lung ventilation was conducted through the whole procedure with the placement of a double lumen endotracheal tube. The patient was positioned on his right side with his left side well exposed. Four 8-mm ports (the optical port, two working ports and an additional assistant port) were advanced into the thoracic cavity (Figure 2). Upon entry to the thorax cavity we saw an abundant amount of omental fat coming from the abdomen through an ellipse-shaped defect in the left postero-lateral part of the diaphragm and reaching the superior lobe of the collapsed lung. Adhesions between the fat and lung were also present (Figure 3A, B). By achieving a reverse Trendelenburg position and inducing a pneumothorax (CO<sub>2</sub> flow: 1 L/min; pressure: 10 mmHg), we enabled a small part of the omentum to be reduced into the abdomen. Finally, the ports were secured to the robotic system. We used the DaVinci Xi Robotic surgical system. We resected the omentum near the defect with a robotic radiofrequency vessel-sealer device (Figure 3C). We did the same with the adhesions between the omentum and the lung. We then proceeded with the repair of the defect with simple interrupted sutures in non-

Correspondence: Niel Di Salvo, Sant'Orsola-Malpighi Hospital, Via Massarenti 11, 40138 Bologna, Italy.  
Tel.: +39.388.9066813 – Fax: +39.051.2144619.  
E-mail: neildisalvo@hotmail.com

Key words: Congenital diaphragmatic hernia; Bochdalek; Robotic surgery; Thoracoscopic CDH repair.

Contributions: the authors contributed equally.

Conflict of interest: the authors declare no potential conflict of interest.

Funding: none.

Received for publication: 7 September 2017.

Revision received: 10 May 2018.

Accepted for publication: 15 May 2018.

This work is licensed under a Creative Commons Attribution NonCommercial 4.0 License (CC BY-NC 4.0).

©Copyright M. Lima et al., 2018

Licensee PAGEPress, Italy

*La Pediatria Medica e Chirurgica* 2018; 40:173

doi:10.4081/pmc.2018.173

absorbable braided material (Figure 3D). The fat tissue previously resected was removed by widening of the trocar ports (2-cm incision). One thoracic drain was put in place and then removed on the III post-operative day after x-ray control (no significant out-put registered). The trocar sites were then closed. Post-operative course was uneventful and the patient was discharged on day IV. Chest x-ray at a one-month check up was normal (no signs of effusion or hernia recurrence).

## Discussion

CDH is a major malformation that consists of a defect of the diaphragm that allows passage of abdominal contents into the thorax causing serious problems in the development and function of the cardio respiratory system. BH is the most frequent type and is defined as a postero-lateral diaphragmatic defect (more frequent in the left side), through which abdominal contents can migrate into the thorax. CDH has always been a big challenge for pediatric surgeons, as its presence is evident soon in the first hours of life with symptoms related to respiratory distress. It is therefore a perinatal pathology associated with significant morbidity and mortality. Rarely, these hernias present later in life, some even in adulthood, like in our case. Only few reports describe adult patients diagnosed with BH. Brown *et al.*<sup>2</sup> and Machado<sup>3</sup> have extensively reviewed all these reports with the purpose of providing clinicians with an outline for the presentation, work-up and surgical management for adult patients with BH. The incidence is reported to be 0,17% with the majority of hernias occurring on the left side and in male patients.<sup>4</sup> There is a general belief, however, that the incidence of BH is much higher than this as supported by two recent reports.<sup>5,6</sup> The high incidence of BH in these studies has been attributed to the high clarity in the definition of structural abnormality with multidimensional CT. The diagnosis of BH is often difficult to make in adults due to the wide variation in their presenting symptoms and the rarity of this hernia defect. Several factors that raise the intra-abdominal pressure may predispose to it, with pregnancy being the most predominant. While most of these hernias are symptomatic and present with pain or complications such as strangulation, there are others that are detected

incidentally, during investigations for other causes.<sup>2</sup> Misdiagnosis or delay in diagnosis are frequent events, unfortunately leading to serious consequences<sup>7</sup> such as strangulation and death. From analyzed literature it is suggested that left-sided defects may be more likely to produce symptoms than right-sided defects, perhaps due to the liver avoiding the herniation of abdominal contents. Most authors recommend hernia repair for all fit surgical candidates regardless of symptoms and even for those patients who are asymptomatic and diagnosed incidentally on abdominal imaging. The concept in favor of such an approach is that a significant number of these patients present acutely with serious complications such as strangulation of the gut leading to severe morbidity and mortality.<sup>2,3</sup> This is why we proposed a surgical correction to our patient. In fact, besides having suffered from recurrent respiratory tract infections during childhood, he was diagnosed because of his dorsal pain. It is difficult for us to be sure whether the pain was related to the hernia or to any other unknown cause. A longer clinical follow-up will probably let us understand such relationship. On the contrary, a wait-and-see approach has been applied by Takahashi *et al.*<sup>8</sup> to 2 patients with no symptoms of BH and no digestive tract herniation.

Many surgical approaches have been tried for this pathology, both open (laparotomy or thoracotomy) and minimally invasive (laparoscopic or thoracoscopic). A minimally invasive technique, especially laparoscopic, is used often for CDH in adults in an elective setting, though rarely for emergency cases. We have gained a certain experience in the thoracoscopic correction of CDH in the pediatric age. The distinct advantages of this approach are that it is minimally invasive and allows the release of adhesions between the herniated viscera and thoracomedial structures under direct vision, before reducing them into the abdominal cavity. The reduction is facilitated by the reverse Trendelenburg position and CO<sub>2</sub> insufflation into the thoracic cavity. In English literature only 8 adult cases using the thoracoscopic approach have been reported.<sup>9-15</sup> In our case, we had the chance to use the robot-assistance to conventional thoracoscopy which has never been described to date. The advantages of such assistance are attributed to wristed instrumentation with 7 degrees of freedom, a better ergonomics of the surgeon and 3D visualization. In our case, robotic technology allowed us to get a perfect visualization of the anatomy and to easily taper the surgical technique to the patient's condition obtaining effective treatment.

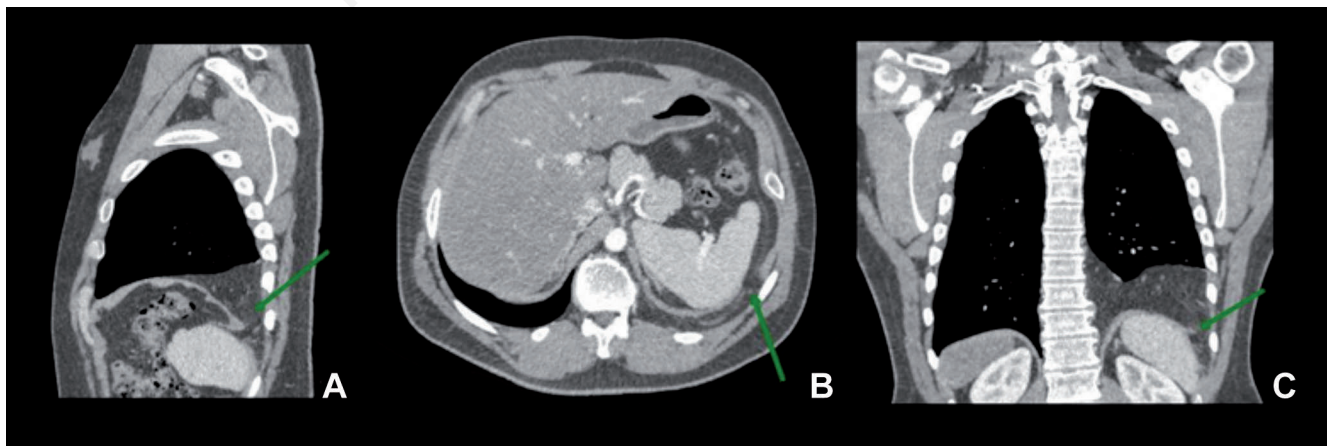


Figure 1. Computed tomography scan. The three sections (A, sagittal; B, axial; C, coronal) revealed a left sided herniation of abdominal contents (omental fat) into the thorax. The green arrows show discontinuity of the soft tissue lines of the diaphragm.

## Conclusions

BH represents a rare entity in the adult population. Its actual incidence, the relationship between its presence and symptoms and therefore indications for surgery are not clear even though the majority of authors, being aware of the possible severe complications, recommend surgical correction in all cases. The use of thoracoscopy is a safe surgical approach in an elective environment with low morbidity and shorter hospital stay and therefore surgeons familiar with these techniques should consider a minimally invasive approach when treating patients with BH. Furthermore the use of robot-assistance to thoracoscopy could facilitate surgeons in the future to achieve correction.

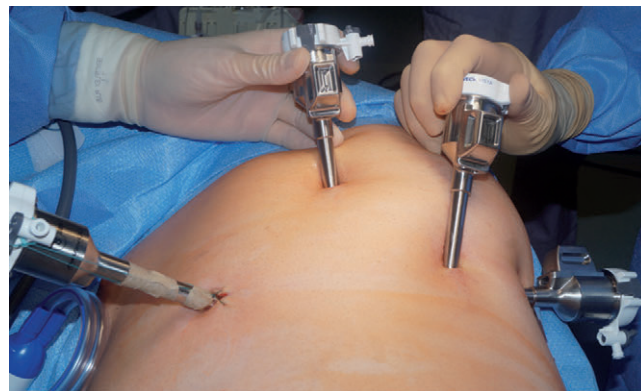

Figure 2. Four 8 mm-ports were advanced into the thorax after a right lateral decubitus was achieved.

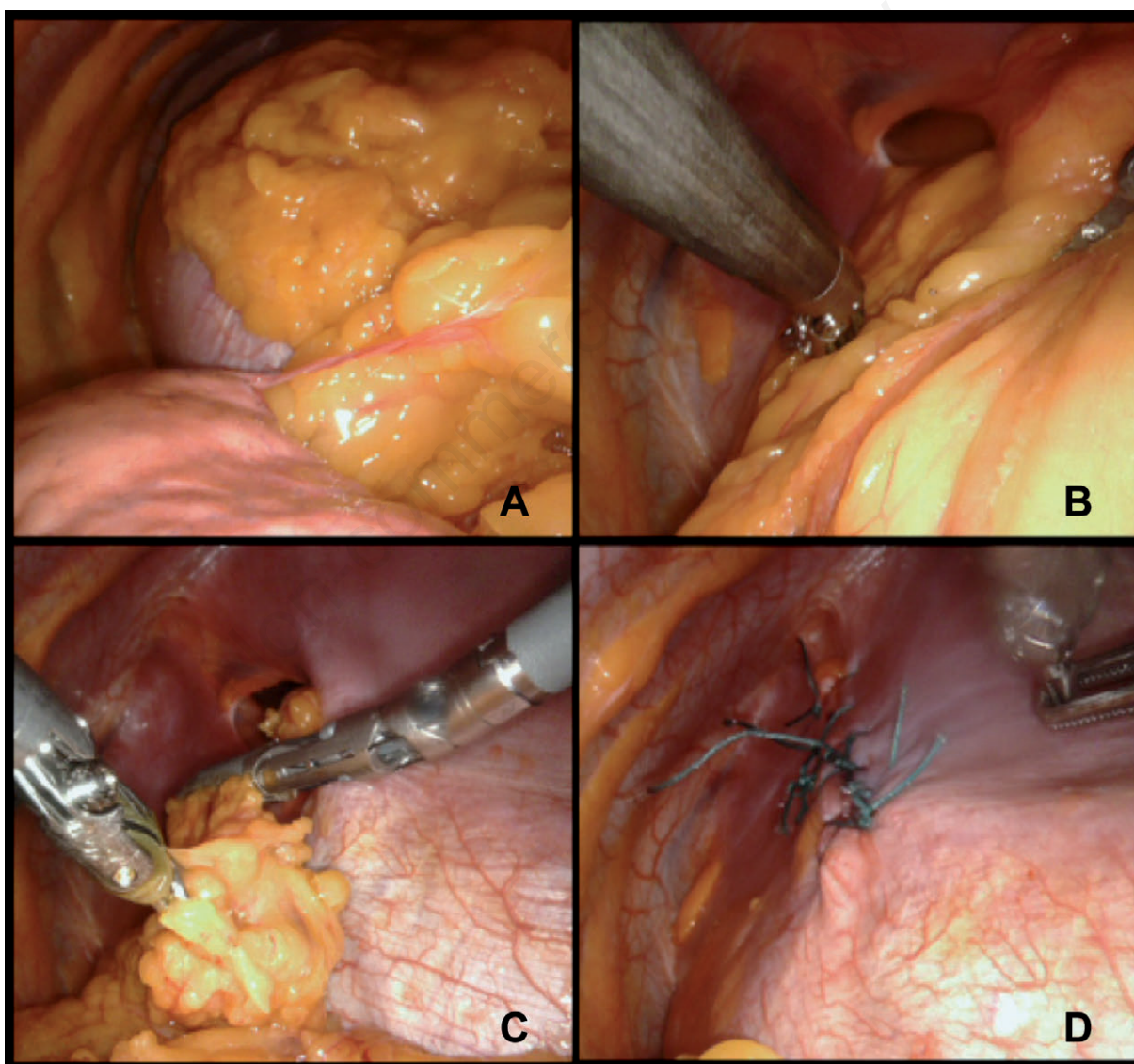


Figure 3. Once entered the thoracic cavity, abundant omental fat was seen coming from the abdomen through a diaphragmatic defect. The fat lied on the collapsed lung up to the superior lobe. Adhesions between the fat and lung were also present (A, B); we resected the omentum near the diaphragmatic defect with a robotic radiofrequency vessel-sealer device (C); the diaphragmatic defect was finally closed with simple interrupted sutures in non-absorbable braided material (D).

## References

1. Molinaro F, Angotti R, Ferrara F, et al. Congenital diaphragmatic hernia. In: Lima M, ed. Pediatric thoracic surgery. Milan: Springer; 2013. pp 227-232.
2. Brown SR, Horton JD, Trivette E, et al. Bochdalek hernia in the adult: demographics, presentation, and surgical management. *Hernia* 2011;15:23-30.
3. Machado NO. Laparoscopic repair of Bochdalek diaphragmatic hernia in adults. *N Am J Med Sci* 2016;8:65-74.
4. Mullins ME, Saini S. Imaging of incidental Bochdalek hernia. *Semin Ultrasound CT MR* 2005;26:28-36.
5. Temizöz O, Gençhellaç H, Yekeler E, et al. Prevalence and MDCT characteristics of asymptomatic Bochdalek hernia in adult population. *Diagn Interv Radiol* 2010;16:52-5.
6. Kinoshita F, Ishiyama M, Honda S, et al. Late-presenting posterior transdiaphragmatic (Bochdalek) hernia in adults: Prevalence and MDCT characteristics. *J Thorac Imaging* 2009;24:17-22.
7. Thomas S, Kapur B. Adult Bochdalek hernia-clinical features, management and results of treatment. *Jpn J Surg* 1991;21:114-9.
8. Takahashi R, Akamoto S, Nagao M, et al. Follow-up of asymptomatic adult diaphragmatic hernia: should patients with this condition undergo immediate operation? A report of two cases *Surg Case Rep* 2016;2:95.
9. Mousa A, Sanusi M, Lowery RC, et al. Hand-assisted thoracoscopic repair of a Bochdalek hernia in an adult. *J Laparoendosc Adv Surg Tech A* 2006;16:54-8.
10. Sato Y, Ishikawa S, Onizuka M, et al. Thoracoscopic repair of diaphragmatic hernia. *Thorac Cardiovasc Surg* 1996;44:54-5.
11. Silen ML, Canvasser DA, Kurkchubasche AG, et al. Video-assisted thoracic surgical repair of a foramen of Bochdalek hernia. *Ann Thorac Surg* 1995;60:448-50.
12. Yamaguchi M, Kuwano H, Hashizume M, et al. Thoracoscopic treatment of Bochdalek hernia in the adult: report of a case. *Ann Thorac Cardiovasc Surg* 2002;8:106-8.
13. Nakashima S, Watanabe A, Hashimoto M, et al. Advantages of video-assisted thoroscopic surgery for adult congenital hernia with severe adhesions: Report of two cases. *Ann Thorac Cardiovasc Surg* 2011;17:185-9.
14. Tokumoto N, Tanabe K, Yamamoto H, et al. Thoroscopic-assisted repair of a bochdalek hernia in an adult: A case report. *J Med Case Rep* 2010;4:366.
15. Frisoni R, Germain A, Ayav A, et al. Thoroscopic treatment of a right Bochdalek hernia in an adult (with video). *J Visc Surg* 2014;151:239.