

# Laparoscopic treatment of symptomatic simple renal cysts in children: single-center experience

Antonio Marte, Lucia Pintozzi

Department of Pediatric Surgery, University of Campania Luigi Vanvitelli, Naples, Italy

## Abstract

Simple renal cysts, although common in adults, are rare in children. They are usually discovered incidentally in the course of the study of other urinary tract symptoms, although they are not always asymptomatic. Renal cysts can be classified as being either simple or complex. The purpose of this review is to present our case series of simple symptomatic renal cysts treated with laparoscopy. Nineteen patients with symptomatic renal cysts (6 to 13.5 cm) were referred to our institution between January 2006 and January 2017. They comprised 12 (40.5%) females and seven (59.5%) males, aged 8 to 15, with a mean age of 12.2 years. Of these patients, nine had previously been treated unsuccessfully by ultrasound-guided aspiration/alcoholization with 95%-ethanol, between 9 and 13 months prior to the laparoscopy. Five patients had undergone one treatment and four had undergone two treatments. All of the patients were treated by laparoscopic three-trocar deroofing. The cysts were opened and the wall excised using scissors and a monopolar hook. In most cases, to better handle the edges of the cyst and obtain a better grip, a needle was used to aspirate a small amount of fluid (used for cytological examination). The wall of the cyst was excised, the cyst edges were sealed, and the perirenal fat was placed on the bottom of the cyst (wadding technique). The mean operating time was 95 minutes (range 50-

150). The postoperative course was uneventful for all of the patients. The hospital stay ranged from one to three days. All of the patients were asymptomatic following the treatment. At a mean follow-up time of 3.6 years, none of the patients had experienced a recurrence. Renal function, as assessed by a MAG3 renal scintigraphy scan, was well-preserved in all of the patients, and all of them undergo an annual ultrasound scan.

## Introduction

Simple renal cysts (SRCs), although common in adults, are rare in children. They are usually discovered incidentally in the course of the study of other urinary tract symptoms, although they are not always asymptomatic. Renal cysts can be classified as being either simple or complex.<sup>1</sup>

These criteria include: i) absence of internal echoes; ii) posterior enhancement; iii) a round/oval shape; iv) sharp/thin posterior walls. The management of SRCs is still controversial, as several procedures are available. The purpose of this review is to present our case series of simple symptomatic SRCs treated with laparoscopy.

## Materials and Methods

Between January 2006 and January 2017, 19 patients with symptomatic renal cysts were referred to our institution. They comprised 12 (40.5%) females and seven (59.5%) males, aged 8 to 15, with a mean age of 12.2 years. All of the patients exhibited type I-II renal cysts, 6 to 13.5 cm, according to the Bosniak classification. Small asymptomatic simple cysts (*i.e.* <5 cm) and renal cysts of higher grade (*e.g.* type IIF, III, and IV according to the Bosniak classification) were excluded from this case-series. Of these patients, nine had previously been treated unsuccessfully by ultrasound (US) guided aspiration/alcoholization with 95%-ethanol, between 9 and 13 months prior to the laparoscopy with cyst size between 7 to 9 cm. Five patients had undergone one treatment and four had undergone two treatments.

The laterality of the cysts was as follows: right kidney, 8 (42.10%), left kidney, 11 (57.89%). Nine cysts were located at the upper pole, seven at the lower pole, and three in the middle/peripelvic position.

Twelve were located on the anterior surface and seven posteriorly. The surgery indication included patients with symptomatic SRC (>6 cm) and those in whom the size of renal cyst enlarged in a short time.

The main symptoms were side pain in all of the patients; a rapid

Correspondence: Antonio Marte, Department of Pediatric Surgery, University of Campania Luigi Vanvitelli, Largo Madonna delle Grazie 1, 80138 Naples, Italy.

Tel.: +39.081.5665413 - Fax +39.081.5665992.

E-mail: antonio.marte@yahoo.it

Key words: Renal cyst; Laparoscopy; Children.

Contributions: the authors contributed equally.

Conflict of interest: the authors declare no potential conflict of interest.

Funding: none.

Received for publication: 23 August 2017.

Revision received: 28 November 2017.

Accepted for publication: 17 March 2018.

This work is licensed under a Creative Commons Attribution NonCommercial 4.0 License (CC BY-NC 4.0).

©Copyright A. Marte, L. Pintozzi, 2018

Licensee PAGEPress, Italy

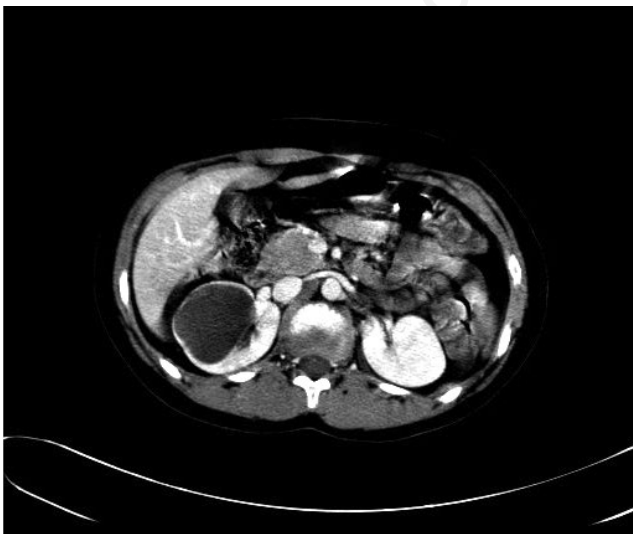
La Pediatria Medica e Chirurgica 2018; 40:168

doi:10.4081/pmc.2018.168

increase in the volume of the cyst (>20% in six months) in seven; a urinary tract obstruction in three; macroscopic hematuria in four, due to lower polar cysts obstructing the upper ureter; otherwise unexplainable urinary tract infections in four; and hypertension in one patient. After detecting the cysts by abdominal ultrasonography, a computed tomography (CT) scan according to the Bosniak criteria revealed Bosniak type I or II cysts in all of the cases.<sup>2</sup> Urine cytology as well as a urine analysis by a culture and a test of sensitivity were done in all of the patients.

The patients were treated by laparoscopic deroofting as follows. We used a three-trocar technique. With the patient placed in a supine position and the affected side risen by 30°, a 12-mm Hasson trocar was applied trans-umbilically using the open technique with a 30°, 10 mm optic. Two 5-mm operating trocars were introduced along the midclavicle line in the upper and lower abdomen (in some cases a fourth trocar was necessary to retract the liver). After a Tod's line incision, the kidney was exposed and the cyst localized and freed from adhesions. In most cases, the cyst presented as a blue dome, which was then opened and the wall excised using scissors and a monopolar hook. To better handle the edges of the cyst, a small amount of fluid (used for cytological examination) was aspirated using a needle, in order to reduce the tension and to obtain a better grip. The wall of the cyst was excised circumferentially at its junction with the renal parenchyma using a monopolar hook and/or Liga-Sure, and the removed portion of the cyst wall was sent to a pathologist for a histopathological assessment.

The portion of the cyst lying directly on the kidney surface was sealed using a monopolar hook to prevent fluid from being produced by the cyst lining.<sup>3</sup> The cyst edges were sealed and the perirenal fat was placed on the bottom of the cyst (wadding technique).<sup>4,5</sup> Blood loss was minimal. A drain was placed around the surgical site and removed within 24-48 hours, provided that no urine leak was detected. During the procedure, we did not routinely use ipsilateral ureteral stenting with the bladder filled with methylene blue, reserving this method only for middle-renal cysts. Follow-up included a clinical review and a renal US at 1, 6, and 12 months, with a MAG3 renal scan at six months, then annually thereafter (Figures 1-5).

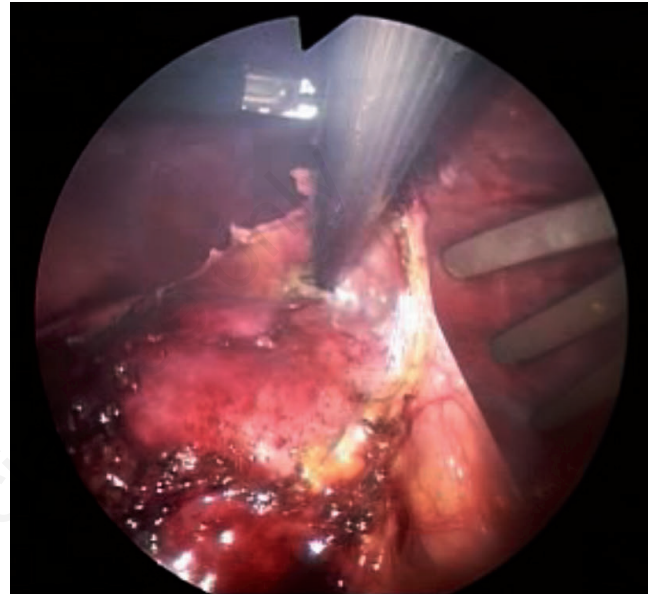


**Figure 1.** 9-year-old girl with chronic side pain and hematuria. Computed tomography scan shows a 8-cm simple symptomatic lower pole right simple renal cyst. The patient had a previous, unsuccessful, ultrasound-guided aspiration/sclerotherapy with 95%-ethanol.

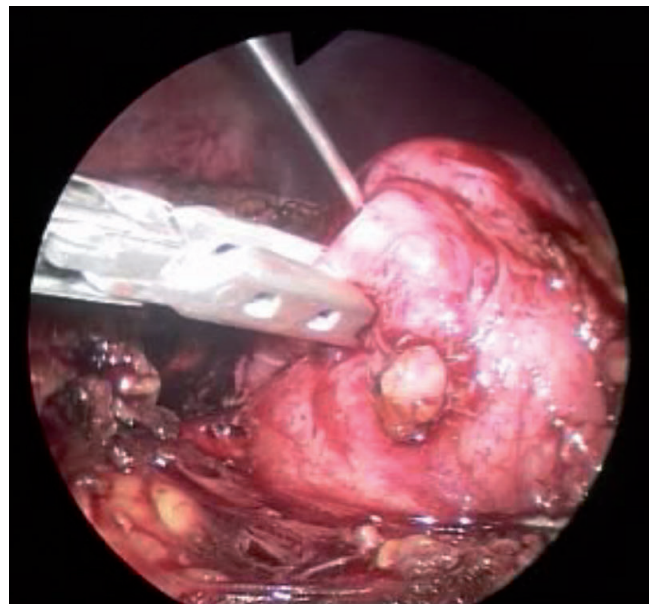
## Results

The mean laparoscopic operating time was 95 minutes (range 50-150). The longest procedure, lasting 150 minutes, involved treatment of a posteriorly located cyst that required more complex maneuvers to isolate of the upper renal pole, due to difficulty controlling blood loss, and the procedure was accomplished without complications.

The post-operative course was uneventful for all of the patients. Hospital stay ranged from one to three days. No particular problem



**Figure 2.** Isolation of the dome of the cyst.

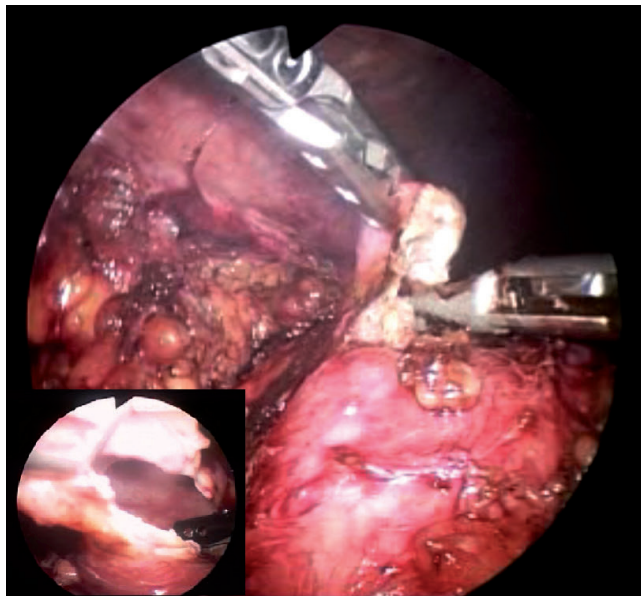


**Figure 3.** Aspiration of fluid under visual control to obtain a better grip and manipulation.

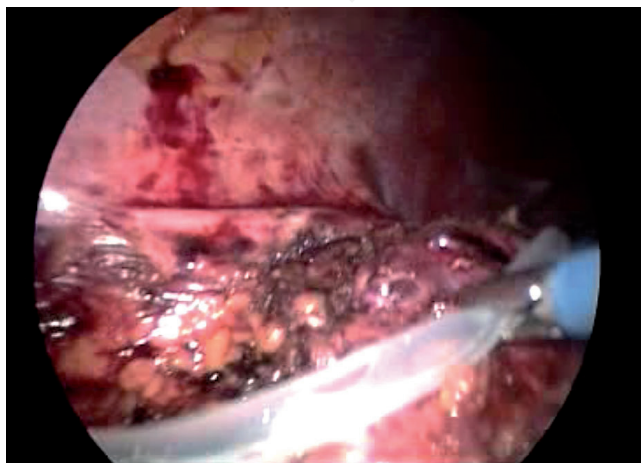
was encountered for patients who had previously been treated by aspiration/alcoholization, except for a degree of omental pericycstic adhesion mainly at the dome of the cyst. A patient with high blood pressure normalized after treatment.

All of the patients were asymptomatic following treatment. At a mean follow-up time of 3.6 years, none of the patients had experienced a recurrence. Renal function, as assessed by a MAG3 renal scintigraphy, was well-preserved in all of the patients, and all of them undergo an annual ultrasound scan.

None of the patients exhibited high blood pressure at the follow-up examination.



**Figure 4.** Deroofing of the cyst with excision of the dome by monopolar hook and Liga-Sure.



**Figure 5.** Wadding of the cyst with perirenal fat and drain.

## Discussion

Treatment of symptomatic renal cysts is still controversial and the pediatric literature is limited in regard to this subject as pediatric cases are often grouped with adults. For asymptomatic cysts without complications, the *wait and see* philosophy seems to be the better solution, particularly in pediatrics.

When a cyst becomes symptomatic, a range of options should be considered: strict US surveillance, aspiration/alcoholization, or surgery. A sudden increase in the size of the cyst, worsening of the pain, hematuria and colic, or the onset of hypertension warrant a more invasive treatment. Simple US-guided aspiration, aspiration/alcoholization, and minimally invasive surgery are still far from providing a definite answer.

Short-term results of simple aspiration are favorable in terms of pain resolution, although long-term results are discouraging as they leave behind the secretive epithelium of the cysts and therefore the cysts can relapse rapidly, with a recurrence rate of 30-80% within two years.<sup>6-8</sup> In regard to the efficacy and safety of aspiration/alcoholization compared to laparoscopic deroofing, random comparative studies are still lacking in the literature, especially in pediatrics.<sup>9</sup>

Percutaneous aspiration/alcoholization of SRCs is a safe and easy procedure, and it can be used to ascertain whether cyst decompression results in the resolution of pain and, if not, it can justify further and more invasive treatment. However, in our experience, nine patients had previously been treated unsuccessfully by US-guided aspiration/alcoholization between 9 to 13 months prior to laparoscopy. Five patients had undergone one treatment and four had undergone two treatments. All of the cysts regressed to their previous size and became symptomatic, requiring laparoscopy.

The explanation of the relapse lies not only in the ineffectiveness of the sclerosing agent, diluted by the fluid remaining in the cyst, but also by the fact that the intracystic folds produced by aspiration would prevent the agent from reaching the cyst epithelium.<sup>10</sup>

In a study comparing aspiration and sclerotherapy with laparoscopic unroofing for management of symptomatic SRCs, some authors found recurrence of pain in all of the patients treated by sclerotherapy after a mean follow-up period of 17 months.<sup>11,12</sup>

The use of laparoscopic surgery to treat renal cysts was first proposed by Hulbert et al. in 1989. It combines the open surgery high success rate with low invasiveness, gaining wide acceptance.<sup>13-15</sup>

In fact, the laparoscopic technique can be limited to deroofing or complete excision of the cystic wall, although the latter entails a high burden from intracystic bleeding and incomplete excision. The preferred technique is deroofing with wadding.<sup>16</sup>

In our experience, laparoscopic management of renal cysts proved highly satisfactory in terms of efficacy, high success rate, minimal morbidity, operating time and hospital stay.

The cosmetic outcome in terms of patient satisfaction is also very encouraging. With regard to the transperitoneal technique, in our experience all procedures were completed with this approach and without any particular problems or blood loss, except for the difficulties encountered with a posterior cyst that required a longer operating time.

On the basis of this experience, we believe that reliable indications for laparoscopic surgery could be: i) failure after aspiration and sclerotherapy; ii) side pain with rapid growth in size; iii) hematuria; iv) cysts that become infected, causing fever, chills, or other signs of infection; v) high blood pressure.

This could represent a reliable guideline, as a recent French review stated that *the management of SRCs in children varies widely*



and the surgical indications are not very precise and they depend on the surgeon.<sup>17</sup>

Other experiences have reported in regard to the possibility of treating pediatric cysts with laparo-endoscopic single-site surgery deroofting, although this is limited to a single case.<sup>18</sup>

As far as retroperitoneoscopy is concerned, this technique has also been used in children with good results.<sup>19</sup>

In a study involving adults, Tefekli *et al.*<sup>20</sup> preferred a retroperitoneal approach for all of the cases in their series, with either anteriorly or posteriorly located renal cysts, and they claimed that it shortened the operating times and hospital stays, as well as nearly eliminating the risk of adjacent organ injury or ileus. In our case study, although a transperitoneal approach was used, we did not encounter problems of this nature and none of the patients required conversion or a blood transfusion.

In the same multicenter review,<sup>17</sup> in which the authors compared SRCs treated by observation alone, or by surgery, they found that the long-term results were similar and the symptoms were not a significant factor influencing surgery. The only significant factor was the preoperative size of the cyst: the larger the cyst, the greater the likelihood that surgery would need to be performed.

Long-term follow-up has confirmed that laparoscopic cyst decortication is an effective and durable treatment option for symptomatic SRCs. The higher success rate and the greater durability of this minimally invasive technique may favor this treatment option over other treatment modalities.<sup>21</sup>

Another issue is that the treatment of renal cysts is still based on the Bosniak classification. The Bosniak renal cyst classification system was initially reported in 1986, using findings from CT scans. Although other imaging modalities are frequently used to evaluate renal masses, such as US and magnetic resonance imaging, CT scans (with and without contrast enhancement) continue to be the primary diagnostic technique. As stated by Bosniak himself: *One of the criticisms regarding the classification is that it is subjective and the line between categories is not sharply defined, resulting in a difference of interpretation among readers.*<sup>22</sup>

## Conclusions

Laparoscopic management of symptomatic SRCs in children can be a highly effective, safe, and useful alternative to sclerotization. Our case study shows that a laparoscopic approach provides satisfactory and lasting results in terms of efficacy, minimal complications, operating time, minimal blood loss, hospital stay, and cosmesis, as well as in case of failure of aspiration/alcoholization.

## References

- Bosniak MA. The current radiological approach to renal cysts. *Radiology* 1986;158:1-10.
- Israel GM, Hindman N, Bosniak MA. Evaluation of cystic renal masses: comparison of CT and MR imaging by using the Bosniak classification system. *Radiology* 2004;231:365-71.
- Nieh PT, Bihrl WIII. Laparoscopic marsupialization of massive renal cyst. *J Urol* 1993;150:171-3.
- El-Shazly M, Allam A, Hathout B. Laparoscopic decortication of simple renal cyst with omental wadding technique: single-center experience. *J Laparoendosc Adv Surg Tech A* 2012;22:886-8.
- Porpiglia F, Fiori C, Billia M, et al. Retroperitoneal decortication of simple renal cysts vs decortication with wadding using perirenal fat tissue: results of a prospective randomized trial. *BJU Int* 2009;103:1532-6.
- Wahlqvist L, Grumstedt B. Therapeutic effect of percutaneous puncture of simple renal cyst. Follow-up investigation of 50 patients. *Acta Chir Scand* 1966;132:340-7.
- Raskin MM, Poole DO, Roen SA, Viamonte MJr. Percutaneous management of renal cysts: results of a four-year study. *Radiology* 1975;115:551-3.
- Hanna RM, Dahniya MH. Aspiration and sclerotherapy of symptomatic simple renal cysts: value of two injections of a sclerosing agent. *AJR Am J Roentgenol* 1996;167:781-3.
- Skolarikos A, Laguna MP, de la Rosette JJ. Conservative and radiological management of simple renal cysts: a comprehensive review. *BJU Int* 2012;110:170-8.
- Cho DS, Ahn HS, Kim SI, et al. Sclerotherapy of renal cysts using acetic acid: a comparison with ethanol sclerotherapy. *Br J Radiol* 2008;81:946-9.
- Okeke AA, Mitchelmore AE, Keeley FX, Timoney AG. A comparison of aspiration and sclerotherapy with laparoscopic de-roofing in the management of symptomatic simple renal cysts. *BJU Int* 2003;92:610-3.
- Arisan S, Dalkilinc A, Caskurlu T, et al. Laparoscopic unroofing and aspiration-sclerotherapy in the management of symptomatic simple renal cysts. *Sci World J* 2006;6:2296-301.
- Hulbert JC, Shepard TG, Evans RE. Laparoscopic surgery for renal cystic disease (abstract). *J Urol* 1992;147:433A.
- Hulbert JC. Laparoscopic management of renal cystic disease. *Semin Urol* 1992;10:239-41.
- Rubenstein SC, Hulbert JC, Pharand D, et al. Laparoscopic ablation of symptomatic renal cysts. *J Urol* 1993;150:1103-6.
- Morgan CJr, Rader D. Laparoscopic unroofing of a renal cyst. *J Urol* 1992;148:1835-6.
- Koutlidis N, Joyeux L, Méjean N, Sapin E. Management of simple renal cyst in children: French multicenter experience of 36 cases and review of the literature. *J Pediatr Urol* 2015;11:113-7.
- Khambati A, Wehbi E, Farhat WA. Laparo-endoscopic single site surgery in pediatrics: Feasibility and surgical outcomes from a preliminary prospective Canadian experience. *Can Urol Assoc J* 2015;9:48-52.
- Rassweiler JJ, Seemann O, Frede T, et al. Retroperitoneoscopy: experience with 200 cases. *J Urol* 1998;160:1265-9.
- Tefekli A, Altunrende F, Baykal M, et al. Retroperitoneal laparoscopic decortication of simple renal cysts using the bipolar PlasmaKinetic scissors. *Int J Urol* 2006;13:331-6.
- Atug F, Burgess SV, Ruiz-Deya G, et al. Long-term durability of laparoscopic decortication of symptomatic renal cysts. *Urogy* 2006;68:272-5.
- Bosniak MA. The Bosniak renal cyst classification: 25 years later. *Radiology* 2012;262:781-5.