

# Secondary hydrosalpinx in adolescents: a challenging decision-making process for surgical choice and future fertility preservation

Angela Riccio,<sup>1</sup> Gabriele Lisi,<sup>1</sup> Maria Enrica Miscia,<sup>1</sup> Gilda Di Paolo,<sup>2</sup> Giuseppe Lauriti,<sup>1</sup> Pierluigi Lelli Chiesa<sup>1</sup>

<sup>1</sup>*Pediatric Surgery Unit, Hospital "Spirito Santo", Pescara - University "G. d'Annunzio", Chieti-Pescara;* <sup>2</sup>*Service of Pediatric and Adolescent Gynecology, Department of Medicine and Aging Science, University "G. d'Annunzio" of Chieti-Pescara, Italy*

## Abstract

Hydrosalpinx in pre-pubertal children and non-sexually active adolescents is a rare finding with several etiology and negative

impact on future female fertility. The therapeutic approach in these specific populations is debated and it must consider its etiology and adult guidelines focused on fertility issues, which suggest laparoscopic salpingectomy. We described two adolescent cases (15 years asymptomatic and 13 years with abdominal pain) presenting a mono-lateral hydrosalpinx secondary to surgery for Hirschsprung's disease and complicated appendicitis, respectively. Both patients underwent to uncomplicated robotic-assisted salpingectomy, with uneventful follow-up and preserved ovarian function. Robotic-assisted salpingectomy for hydrosalpinx secondary to previous surgical conditions is a safe and careful approach for adolescents in order to preserve ovarian vascularization, function and future fertility.

Correspondence: Gabriele Lisi, Department of Pediatric Surgery, Hospital "Spirito Santo" of Pescara - University "G. d'Annunzio" of Chieti-Pescara, Via Fonte Romana 8, 65124 Pescara, Italy.  
E-mail: gabriele.lisi@unich.it

Key words: Adolescent; fallopian; hydrosalpinx; robot; salpingectomy.

Acknowledgments: All member groups, the patients and their families are acknowledged for their collaboration for making this study possible.

Contributions: AR, MEM, GDP and NM gave substantial contribution to the acquisition of data and to drafting of the work. GLi gave substantial contribution to the design of the work, to drafting of the paper and gave critical revision for important intellectual content. GLa and PLC gave substantial contribution to the interpretation of data and critical revision for important intellectual content. All the authors approved the final version to be submitted for publication and agree to be accountable for all the aspect of the work in ensuring that questions related to the accuracy or integrity of any part of the work are appropriately investigated and resolved.

Conflict of interests: The authors declare no conflicts of interest.

Availability of data and materials: All data underlying the findings are fully available.

Ethics approval and consent to participate: No ethical committee approval was required for this case report by the Department, because this article does not contain any studies with human participants or animals. Informed consent was obtained from the patient included in this study.

Consent for publication: The patients' guardians gave their written consent to use the patients' personal data for the publication of this case report and any accompanying images.

Received for publication: 19 May 2020.  
Accepted for publication: 18 January 2021.

This work is licensed under a Creative Commons Attribution NonCommercial 4.0 License (CC BY-NC 4.0).

©Copyright: the Author(s), 2020  
Licensee PAGEPress, Italy  
La Pediatria Medica e Chirurgica 2020; 42:233  
doi:10.4081/pmc.2020.233

## Introduction

Hydrosalpinx (HS) is a fluid-filled dilatation of the Fallopian tube due to a distal obstruction involving entirely or partially the tubal structure. The tubal obstruction could be primary or secondary to other conditions, such as pelvic inflammatory disease, endometriosis, neoplasms and post-operative abdomino-pelvic adhesions. HS is an uncommon finding among paediatric and adolescent populations and in general among not-sexually active women. Usually HS is asymptomatic and incidentally diagnosed, but it could be eventually related with tubal torsion and acute abdominal pain,<sup>1,2</sup> infection or infertility in adult women who are trying to get pregnant. The related literature in adulthood focuses mainly on infertility and risk of pregnancy loss (relative risk increase 74%).<sup>3</sup> HS could also cause the unsuccess of in vitro fertilization (IVF) and it should be previously treated to increase pregnancy's chances when tubal factors influence fertility.<sup>4</sup> Several therapeutic approaches to HS for pre-menarche and adolescent patients are described: observational with ultrasonographic follow-up, conservative medical (antibiotics, hormonal replacement), conservative surgical (detorsion if necessary, tubal drainage, salpingostomy, tubal occlusion) or ablative (total or partial salpingectomy).<sup>5</sup> Although laparoscopic salpingectomy remains the first surgical choice for HS in adulthood and childhood, conservative managements have been recently proposed as options comparable to ablative surgery by different Authors,<sup>2</sup> especially focusing on short-term follow-up of non-adult patients.<sup>6</sup> However, these conservative approaches are mainly reported for primary HS and lack of follow-up on later fertility.

We present and discuss two cases of adolescent girls underwent robot-assisted salpingectomy for mono-lateral hydrosalpinx secondary to previous abdomino-pelvic surgery.

## Case Reports

### Case #1

A fifteen years-old girl, born with a recto-sigmoid congenital aganglionosis managed at birth with a Nixon's colostomy followed by a laparotomic Soave's pull-through procedure, was referred to our Paediatric and Adolescent Gynaecology Service because of a primary amenorrhoea. Clinical examination and blood exams, included hormonal studies (FSH, LH, Prolactin), were within the normal. An abdomino-pelvic ultrasound scan revealed regular uterus and ovaries, and the presence of an an-echogenic 6x5 cm oval image in the left hemipelvis, proximal to the homolateral ovary, not clearly referable to adnexa or intestine. Neoplastic markers resulted negative. An MRI-scan showed a tubular and convolute mass (6x2x4cm) into the left hemipelvis, in contiguity with a slightly anteriorly dislocated left gonad. The mass resulted T2-hyperintense and T1-hypointense, with liquid content, regular wall (maximum thickness of 3mm) and homogeneous contrast enhancement (Figure 1A-B). This finding was compatible with a Fallopian tube dilatation. The girl underwent regular ultrasound follow-up but, meanwhile menarche occurred, the lesion slightly increased its volume. After discussing with parents and patient risks and advantages of both conservative and operative approaches, they opted in favour of a surgical treatment. The approach chosen was a robotic-assisted (DaVinci-Xiã) left salpingectomy. The patient was placed supine, in Trendelenburg position. Three 8mm trocars for robotic instruments were inserted (a trans-umbilical for the camera, a left paraumbilical and a right paraumbilical for scissors and grasper) and one further laparoscopic 5.8mm trocar for the AirSealã at left hypochondrium was added to assist robotic instruments. Several adhesions between left colon and parietal wall were dissected at level of left iliac fossa, revealing the homolateral ovary laterally pulled up behind the left colon. Medially the distended left Fallopian tube was evident. The tube was progressively isolated up to the tubal-uterine junction and from the left gonad. Salpingectomy was performed using a hybrid device (Thunderbeatã) that combines ultrasonic and advanced bipolar energy, leaving untouched left ovary's blood supply. (Figure 1C) The specimen (6x1.3cm) was exteriorized through the umbilical incision, no drainage needed. Hospital stay was uneventful and pain-

less, and the patient was discharged home on third post-operative day. Histological examination detected a thin tubal wall lacking in mucosal folds and hyperplastic epithelium, with acute and chronic transmural inflammatory infiltrate. At 1 year of follow-up, the girl is asymptomatic with regular periods. Pelvic ultrasound shows a normal sized left ovary with follicular aspect.

### Case #2

A 13 years-old post-menarche girl, previously operated, at 4 years-old, because of a peritonitis secondary to appendicitis, was admitted to our Department with right acute abdominal and pelvic pain. Blood exams were within the normal, but an abdominal ultrasound showed a right ovarian haemorrhagic luteal body and a 4x3x7cm large echogenic cystic tubal mass (Figure 2). Neoplastic markers were within normal ranges. A first conservative management was chosen, and the patient was enrolled in gynaecologist-driven ultrasound follow-up. After 3 weeks the girl had a further episode of acute abdominal pain, with unchanged ultrasound findings. MRI-scan well defined a T2-hyperintense, 4cm large functional right ovarian cyst and a S-shaped simple cystic dilatation of the right fallopian tube, with thin wall and maximum diameter of 3,5cm (Figure 3A-B). In agreement with the parents, we performed a laparoscopic right ovarian cystectomy and an extended lysis of adhesions between caecum and right iliac fossa, in order to facilitate a possible decompression of the right fallopian tube. Histology confirmed a lutein cyst. Post-surgically, a hormonal combined therapy was prescribed to help reduce right tubal dilatation. Ultrasound studies performed after three-months showed nor resolution neither reduction of the hydrosalpinx. After further discussion with patient and parents, a robotic-assisted right salpingectomy was planned. Robotic trocars and instruments were inserted as previously described. Difficult and careful adhesions lysis and isolation of the right HS from the gonad was carried out through hybrid device (Thunderbeatã) with complete preservation of the right ovary and its vessels. The girl was discharged home the third post-operative days without complications; histological examination confirmed the diagnosis of hydrosalpinx with acute and chronic inflammatory infiltrate. At 8 months follow-up the girl is asymptomatic with regular periods, under combined hormonal therapy. Pelvic ultrasound shows a normal sized right ovary with follicular aspect.

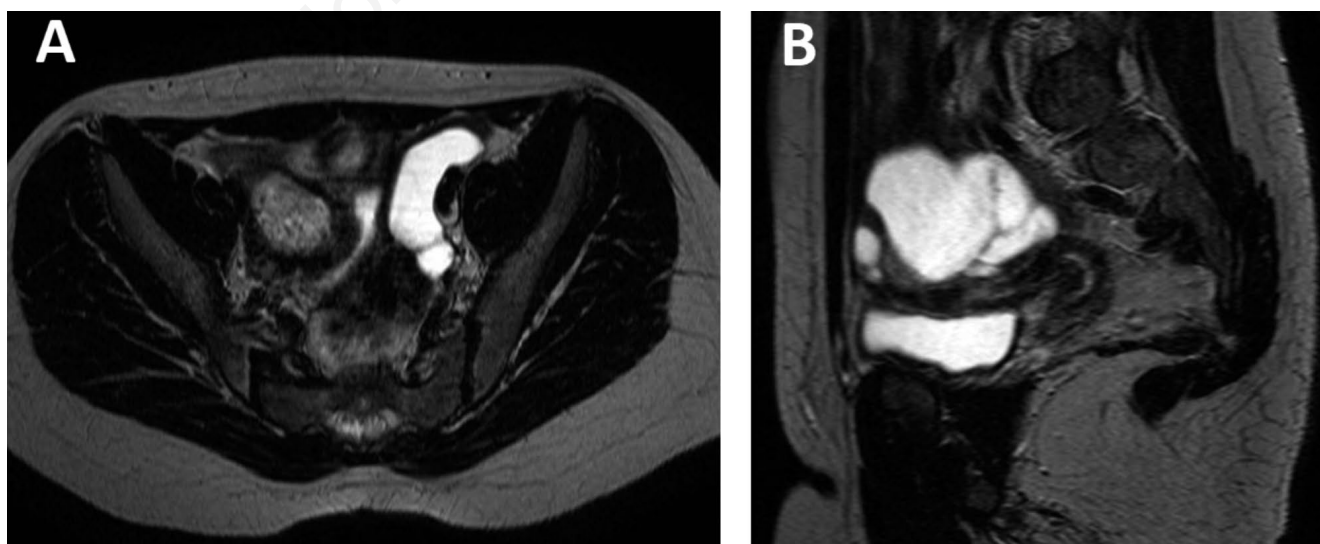


Figure 1. Case 1: A) transverse and B) sagittal section of T2W-MRI scan of left Fallopian tube dilatation.

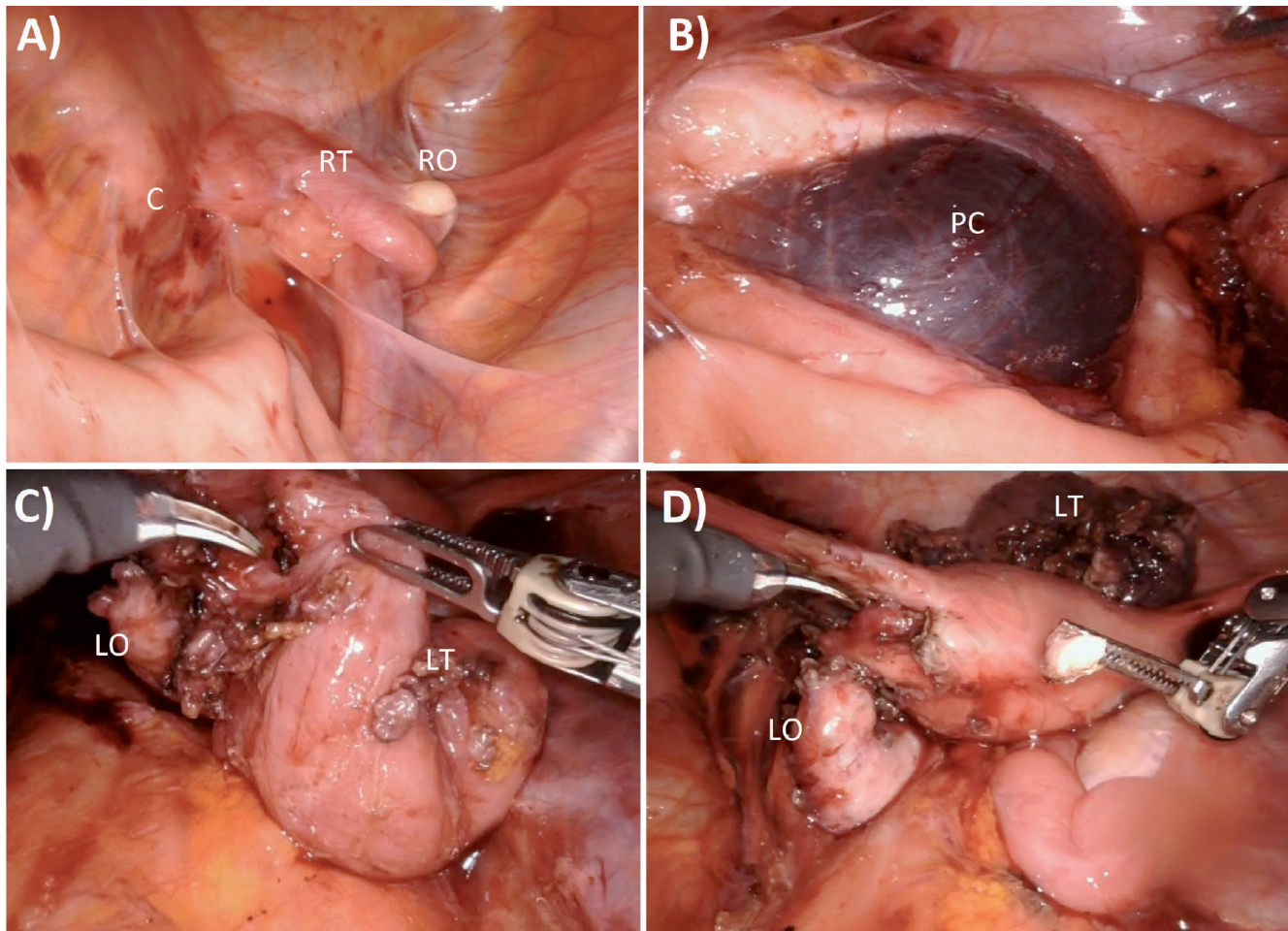


Figure 2. Case 1: Intraoperative frames: A) first view of low abdominal cavity with an unclear structure strictly surrounded by adhesions B) Lysis of adhesions to gain a rightly anatomical view C) After accomplished a complete restore of the pelvic space, all the internal genitals could be defined and the dilated left tube was gradually isolated D) left ovary completely isolated from the omolateral tube, visible on its right, still in continuity with the uterus before its section.

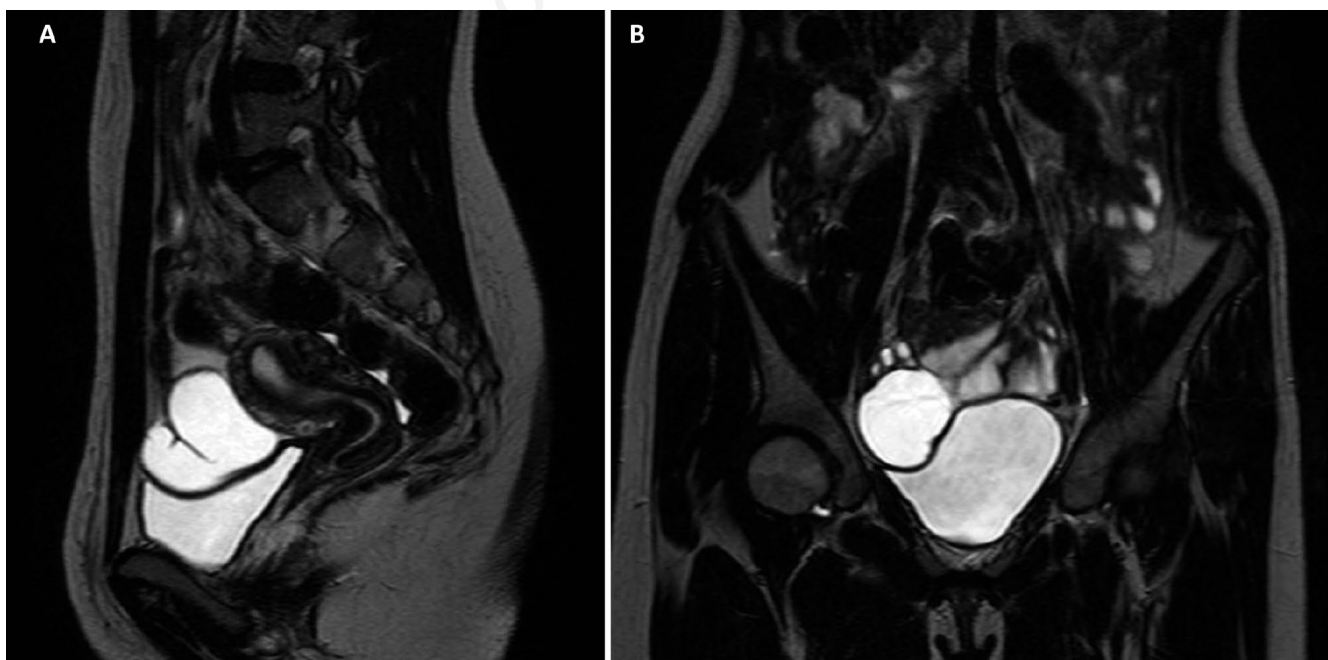

Figure 3. Case 2: A) transverse and B) sagittal section of T2W-MRI scan of right fluid-filled S-shaped Fallopian tube.

## Discussion

Incidence and aetiology of HS in pre-pubertal and adolescent girls are debated, as well its treatment. Primary HS seems to be related with hormonal changes during peri-pubertal time, and especially FSH increased levels could unmask a pre-existent distal tubal obstruction stimulating ovarian and tubal function.<sup>7</sup> In post-menarche non-sexually active girls HS is usually secondary to abdomino-pelvic surgeries for peritonitis, congenital malformations, or neoplasia.<sup>8</sup> Asymptomatic forms are more frequent compared to the symptomatic ones, which could be characterized by nonspecific signs, more often related to acute pain due to tubal torsion. Our report focuses on two cases of adolescents with a past history of abdomino-pelvic surgery, for Hirschsprung's disease (HD) and complicated appendicitis, respectively.

Other authors have reported cases of hydrosalpinx secondary to HD. Palazon *et al.* includes 5 out of 17 not-sexually active patients who developed bilateral hydrosalpinx after reaching menarche.<sup>7</sup> The treatments chosen were 2 bilateral and 1 unilateral salpingectomy, 1 pyosalpinx evacuation and 1 patient was untreated. Three patients had conception desire: 1 had children; 2 were on IVF program. The authors found a not-statistically significant relation between the type of surgical approach for HD and the risk of post-menarche hydrosalpinx.

Merlini *et al.* published 3 cases of bilateral hydrosalpinx in post-pubertal not-sexually active HD patients underwent 3 different operative approaches (Duhamel's, Soave's and Martin's procedures). One patient was lost to follow-up, the remaining patients were addressed to oral contraceptives, with bilateral improvement after 5 months in the first patient and bilateral resolution after 1 year in the second case. The authors hypothesized that the aetiology of secondary hydrosalpinx in this specific population should be researched into pre-existing pathologic neuro-muscular impairments, instead of surgical choice.<sup>9</sup>

Surgical approach to HS is debated, and the most of literature is focused on adult population, specifically concerned about reproductive life.<sup>10</sup> Although laparoscopic salpingectomy remains the first surgical choice for HS in adulthood and childhood, the results of observational, medical and surgical conservative managements were evaluated in a recent systematic review by Kazmi *et al.*<sup>6</sup> These authors analysed a mixed population of paediatric patients, adolescents and adult women without previous sexual activity, with HS unrelated to ascending pelvic inflammation, and reported comparable results regarding short-term outcomes. However, this paper reveals that ablative surgery is more often performed for HS secondary to previous abdomino-pelvic conditions (7 out of 10 cases, including the patients reported by Merlini).

Despite short and mid-term outcomes for pre-menarche and adolescent patients, the conservative approach to HS proposed by the latter cited paper does not clearly differentiate among primary vs. secondary aetiology and there is lack of data about the long-term impact of this condition on fertility. It is now accepted that fluid within a HS plays a role in reducing by 50% the pregnancy rates in assisted reproductive technology in women with HS, probably due to a combination of mechanical and chemical factors. In 2018 Harb *et al.* published a meta-analysis of 14 observational studies showing a significant 74% relative increase in the risk of pregnancy loss in women with HS vs. women without it.<sup>3</sup> In their study, the authors found that pooling of risk ratios from 7 randomized trials and 6 observational studies of treatment of HS showed a reduction in pregnancy loss of approximately half when compared with no treatment. Based on the current evidences, women with HS should be offered salpingectomy, preferably by

laparoscopy, before IVF treatment because this improves the chance of a live birth.

Someone could speculate about the accuracy of these definitive conclusions, based on the unclear impact of several factors: the different etiologies of HS, the age at onset, the relation between HS duration and fertility impairment, the improvement of currently available IVF methods.<sup>11</sup> These doubts are even more justified in adolescent-onset cases, patients still far from desire of pregnancy, in which the idea of a demolitive surgery could have a negative psychological impact. Furthermore, a correct information on possible future fertility issues should be deeply discussed with caregivers and patients, to share the therapeutic plan.

We therefore opted, after an in-depth debate with patients and families, for a tubal demolitive surgery, in agreement with the majority of literature and worried about a long-term possible negative HS's impact on the reproductive system.

Some authors have highlighted a negative effect of laparoscopic salpingectomy on ovarian function and reserve, secondary to a possible alteration of the ovarian blood flow,<sup>12,13</sup> while the results of other authors exclude this occurrence.<sup>14,15</sup> Faced with these conflicting data on a possible iatrogenic damage on ovarian vascularization, operating close to the fallopian tube and away from the ovarian vessels and suspensory ligament is recommended to minimize devascularization of the ovary.<sup>5</sup>

As highlighted by Ng *et al.* the laparoscopic approach to salpingectomy may be very difficult in presence of tenacious adhesions, such in our cases.<sup>5</sup>

Several factors may limit standard laparoscopy: reduced depth perception of the operative field caused by 2D monitors, poor hand-eye coordination derived by monitor position, variable amplification, motion limitations due to trocar-induced invariant points, reduced haptic feedback.

The technology behind robotic surgery circumvents the limitations of laparoscopy, expanding the surgical arsenal with better 3D magnification, consistent and precise movements of articulated wristed surgical instruments with 5-7 degrees of freedom, and the ability to scale motion thus eliminating physiologic tremors of surgeon. Robotic gynecologic surgery provides additional benefits over other approaches in small and narrow spaces, such as the pelvis.<sup>16</sup>

For the purpose of ovarian preservation, in our limited experience, the robot-assistance was extremely useful to minimize the trauma to the ovarian vessels, thanks to its features mentioned above. Although satisfied with our clinical results, we are cautious about definitive statements sustaining the superiority of robotic approach, given the lack of its clear evidence-based superiority derived from the difficulty to perform randomized controlled trial for this uncommon condition in this young population. The theoretical clinical advantages of the robotic approach must be clearly balanced by its still high costs, which are however destined to decrease shortly, thanks to the imminent entry of new players into the surgical robot market.

## Conclusions

To the best of our knowledge, these are the first reported cases of robot-assisted salpingectomy in adolescent patients with hydrosalpinx secondary to previous abdominal surgery. In our experience, this approach resulted a safe procedure to be considered, in order to avoid vascular damages at the reproductive organs and preserve future fertility, especially in those patients with possible several adhesions after abdomino-pelvic surgeries. Moreover,

robotic approach is perfectly applicable to a narrow anatomical space like pelvis. Future fertility evaluation should be carried out when those patients, treated with salpingectomy in childhood, reach adulthood.

## References

1. Bertozzi M, Noviello C, Molinaro F, et al. Isolated fallopian tube torsion in pediatric age: An Italian multicenter retrospective study. *J Pediatr Surg* 2020;55:711-4.
2. Boukaidi SA, Delotte J, Steyaert H, et al. Thirteen cases of isolated tubal torsions associated with hydrosalpinx in children and adolescents, proposal for conservative management: retrospective review and literature survey. *J Pediatr Surg* 2011;46:1425-31.
3. Harb HM, Al-Rshoud JF, Karunakaran B, et al. Hydrosalpinx and pregnancy loss: a systematic review and meta-analysis. *Reprod Biomed Online* 2019;38:427-41.
4. Volodarsky-Perel A, Buckett W, Tulandi T. Treatment of hydrosalpinx in relation to IVF outcomes: a systematic review and meta-analysis. *Reprod Biomed Online* 2019;39:413-32.
5. Ng KYB, Cheong Y. Hydrosalpinx e Salpingostomy, salpingectomy or tubal occlusion. *Best Pract Res Clin Obstet Gynaecol* 2019;59:41-7.
6. Kazmi Z, Gupta S. Best practice in management of paediatric hydrosalpinges: a systematic review. *Best Pract Res Clin Obstet Gynaecol* 2019;59:41-7.
7. Palazon P, Saura L, de Haro I, et al. Bilateral hydrosalpinx in patients with Hirschsprung's disease. *J Pediatr Surg* 2018;53:1945-50.
8. Cabral MD, Siqueira LM, Hydrosalpinx in postmenarchal non-sexually active girls: a review of 6 cases in a children's hospital. *J Pediatr Adolesc Gynecol* 2015;28:e203-7.
9. Merlini L, Anooshiravani M, Peiry B, et al. Bilateral hydrosalpinx in adolescent girls with Hirschsprung's disease: association of two rare conditions. *AJR Am J Roentgenol* 2008;190:W278-82.
10. Noventa M, Gizzo S, Saccardi C, et al. Salpingectomy before assisted reproductive technologies: a systematic literature review. *J Ovarian Res* 2016;9:74.
11. Van Voorhis BJ, Mejia RB, Schlaff WD, et al. Is Removal of Hydrosalpinges Prior to in Vitro Fertilization the Standard of Care? *Fertil Steril* 2019;111:652-6.
12. Chan CCW, Ng EHY, Li CF, et al. Impaired ovarian blood flow and reduced antral follicle count following laparoscopic salpingectomy for ectopic pregnancy. *Hum Reprod* 2003;18:2175-80.
13. Gelbaya TA, Nardo LG, Fitzgerald CT, Horne G, et al. Ovarian response to gonadotropins after laparoscopic salpingectomy or the division of fallopian tubes for hydrosalpinx. *Fertil Steril* 2006;85:1464-8.
14. Lass A, Ellenbogen A, Croucher C, et al. Effect of salpingectomy on ovarian response to superovulation in an in vitro fertilization-embryo transfer program. *Fertil Steril* 1998;70:1035-8.
15. Luo J, Shi Y, Liu D, et al. The effect of salpingectomy on the ovarian reserve and ovarian response in ectopic pregnancy. A systematic review and meta-analysis. *Medicine* 2019; 98:47-53.
16. Pelizzo G, Nakib G, Calcaterra V. Pediatric and adolescent gynecology: treatment perspectives in minimally invasive surgery. *Pediatric Reports* 2019;11:8029.