

Chronic Monteggia in pediatric population: A narrative literature review

Chiara Arrigoni, Nunzio Catena

Reconstructive Surgery and Hand Surgery Unit, IRCCS Istituto Giannina Gaslini, Genova, Italy

Abstract

Monteggia lesion is a traumatic condition that affects the forearm and is characterized by the association of an ulna fracture with a dislocation of the radius capitellar and proximal radius ulnar joints in the majority of cases. Although several authors have contributed to the understanding of this pathology over the years, it remains a challenge for orthopedists, and if not recognized and treated properly, it can have serious consequences. In these cases, a chronic injury develops, which is even more difficult to manage in terms of timing and treatment options. A narrative review of the

Correspondence: Chiara Arrigoni, Reconstructive Surgery and Hand Surgery Unit, IRCCS Istituto Giannina Gaslini, Via Gerolamo Gaslini 5, 16147 Genova, Italy.
Tel.: 01.0563.62395
E-mail: chiara.arrigoni@libero.it

Key words: Missed Monteggia; chronic Monteggia; child; Bado's classification; Letts's classification.

Funding: None.

Contributions: CA performed the majority of the writing and prepared the figures, NC coordinated the writing of the paper and check the final version before the submission.

Conflict of interest: The authors declare no conflict of interest.

Availability of data and materials: All data generated or analyzed during this study are included in this published article.

Ethics approval and consent to participate: Not applicable.

Informed consent: Not applicable.

Received for publication: 22 September 2022.

Revision received: 4 October 2022.

Accepted for publication: 4 October 2022.

Publisher's note: All claims expressed in this article are solely those of the authors and do not necessarily represent those of their affiliated organizations, or those of the publisher, the editors and the reviewers. Any product that may be evaluated in this article or claim that may be made by its manufacturer is not guaranteed or endorsed by the publisher.

©Copyright: the Author(s), 2022

Licensee PAGEPress, Italy

La Pediatria Medica e Chirurgica 2022; 44(s1):289

doi:10.4081/pmc.2022.289

This work is licensed under a Creative Commons Attribution-NonCommercial 4.0 International License (CC BY-NC 4.0).

literature on missed elbow injuries in children was conducted, and chronic Monteggia was the most frequently encountered injury. The analysis of the articles attempts to clarify some points and draw general conclusions on which to reflect.

Introduction

Monteggia lesion is a traumatic condition that affects the forearm and is characterized, in the majority of cases, by the association of an ulna fracture with a dislocation of the radial head;¹ the first description was attributed to Dr. Giovanni Battista Monteggia who, in 1814, described one of its clinical forms as "a traumatic lesion with a proximal third ulna fracture in association with an anterior dislocation of radial proximal epiphysis".²

Many years later, in 1967, Dr. Jose Luis Bado published a monograph on Monteggia's injury, recognizing four different types in relationship to the site of ulnar fracture and the direction of radial head dislocation.³ Bado's classification is now adopted by a large part of orthopedic surgeons, but seem to be still not comprehensive of other the possible clinical presentations.

In pediatric age, in fact, ulnar fracture may be not so evident, especially in buckle or plastic deformation types, so other specific classifications have been described. One of these, Lett's classification,⁴ for example, classify Monteggia Bado I type as A or 1 if there is a plastic deformation, B or 2 if there is a greenstick fracture, type C or 3 if there is a complete fracture. Type D or 4 is like Bado II and type E or 5 is like Bado III.

Despite the efforts of many authors who contributed during years to increase the comprehension of the different aspect characterizing Monteggia's injury, it remains a challenge for orthopedists, especially for the high rate of missed cases, which can lead to serious consequences due to the difficulty in managing a chronic condition.

To better understand the state of the art and the approach to missed Monteggia, the authors performed a narrative literature review trying to extrapolate the more useful indications for orthopedists' daily work activity.

Materials and Methods

The literature reviews was performed consulting PubMed to identify relevant studies (Figure 1). The search strategy involved English literature up to December 2020 without any filters. The searching strategy used was "elbow fractures AND missed AND children" with the aim to include the greatest number of articles on missed elbow fracture in pediatric population.

Out of 90 articles were found, of which abstracts were analyzed.

Exclusion criteria were articles non coherent with the issue, those in which the population was older than 16 years, those in languages other than English, and double articles; if age was not specified, or the articles that had no abstract or had an unclear abstract were maintained for a second look. Out of 79 articles maintained, 60 were selected after complete text reading using the same criteria. Among them, 42 were identified for review; the remaining articles were eliminated because they focused on acute lesions (diagnosis and treatment by 4 weeks from trauma), patients' aged over 16 years old (clarified in text), treatment of malunion and nonunion, or missed isolated dislocation.

Of these 42 articles, 13 case report and 29 case series were found; being a rare condition, case reports were analyzed too to avoid losing useful information (Figure 1).

A total of 450 patient were represented (Table 1): 284 males, 162 females, and 4 patients (described in one case series) of whom the gender was not specified.

Average age was 7.5 years old (2-14 years), but this parameter is not so reliable because it is not standardized on descriptions (some articles reported the average age at trauma, in others at surgery, in some articles it was indicated in months and years and in others with simple decimal numbers) and it was calculated rounding down.

Even average cure timing of 10.66 months is affected by the high variability with which the information was reported.

Monteggia lesions are the most frequently missed injury (422 out of 450 patients), while in other 28 patients the missed injury were: i) 4 missed medial epicondyle fractures with elbow dislocation (2 posterior, 1 postero-lateral e 1 not specify) e 1 case without a clear dislocation; ii) 1 medial condylar fracture with elbow dislocation; iii) 4 shear fractures of capitulum humeri (1 Kocher-Lorenz and 3 classify as type 2 without the name of classifications); iv) 1 case of epiphyseal fracture-separation of the olecranon; v) 16 cases of epiphyseal fracture-separation of distal humerus; vi) 1 lateral condylar fracture.

All articles except one (in which 95 patients were analyzed) classify Monteggia lesions with Bado's types: i) Type I: 276 cases; ii) Type II: 9 cases; iii) Type III: 34 cases; iv) Type IV: 3 cases; v) Equivalent: 5 cases (with radial head fracture).

Only in 1 article is specified the type of ulnar pediatric frac-

ture: 4 Monteggia lesions are classified as 2 Letts type I, 1 Letts type 2 and 1 Letts type 3.

Monteggia lesions are described in 31 articles (4 case report and 27 case series) with an average age of 6.8 years and average time of 11.6 months at diagnosis.

Regarding clinical signs of chronic lesion, the limitation in range of motion and valgus deviation of the elbow were the main reported respectively in 15 and 12 articles; the third most common was the skin prominence of dislocated radial head, cited in 8 articles, while pain was less common and described in only 6 articles.

Others minor signs were varus isolated ulna deviation, total elbow varus deviation, heterotopic ossification, and capitulum humeri hypoplasia, all described in only 1 article each.

For what concerns neurovascular problems, they were rare: a PIN (posterior interosseus nerve) palsy was described in 6 patients, a radial nerve palsy in 2 patients and an ulnar nerve palsy in 1 patient. Moreover, associated lesions (head trauma in polytrauma) were present only in one patient.

All diagnosis were made by X-rays, only in 1 article the diagnosis followed a CT scan, no MRI was required.

Treatment was widely variable and difficult to summarize; in 395 cases an ulnar flexion and lengthening osteotomy were performed, both progressive and extemporaneously; the surgical access was specified in 13 articles as a Boyd' access.

Several devices were used for osteotomy fixation such as pre-countured plates and screws (296 patients), monoaxial external fixator (53 patients), Kirshner wires (21 patients), Steinman pin (9 patients), circular external fixator according to Ilizarov technique (4 patients), Rush nail (1 patient), endomedullary elastic nails (4 patients), cannulated screw (4 patients), 2 reabsorbable sutures Maxon type (2 cases); 3 patients were treated only with cast immobilization.

Open reduction of radial head dislocation was performed in 369 patients, while in 52 was performed with closed external maneuvers; a temporary radio-humeral joint fixation with K wires was performed in 122 patients; 11 articles reported on open reduction of radial head dislocation; Kocher approach resulted to be the most used but also Kaplan and Henry were cited.

Annular ligament repair or reconstruction was not always reported; a Bell-Tawse reconstruction with a tricipital band strip, was performed in 100 patients while other minor site of grafts were proximal ulnar periosteal sleeve, antebrachial fascia, fascia lata and palmaris gracilis.

In 1 patient reconstruction with an anchor was performed and in 71 patients with direct suture.

In 5 articles, 78 patients, it was specified that no reconstruction was performed, and annular ligament was left interrupted.

Average post-operative immobilization was of 5.4 weeks while in case treated with external fixators (5 monoaxial and 1 circular frame), they were left in place for 9.2 weeks of average.

In 8 articles on 31 (25%) no post-operative complications were noted.

Early complications were reported in 12 patients as an acute radial head re-dislocation treated in 72 hours from first surgery in all but one that refused treated proposed; in 4 patients pin site infections treated with antibiotic therapy; 2 lost of synthesis fixation immediately treated with change from wires to plates, 1 radial nerve partial lesion treated with direct suture and 1 compartmental syndrome treated with immediately fasciotomy.

Late complications affected 43 patients as a new dislocation or an asymptomatic subluxation; 19 patients suffered from ulna nonunion that, in some cases, needed further surgery; in 14 patients early arthritis and in 13 some bone deformity on proximal radial epiphysis; in 8 patients nerve lesions (5 of PIN and 3 of ulnar nerve) but none required surgery.

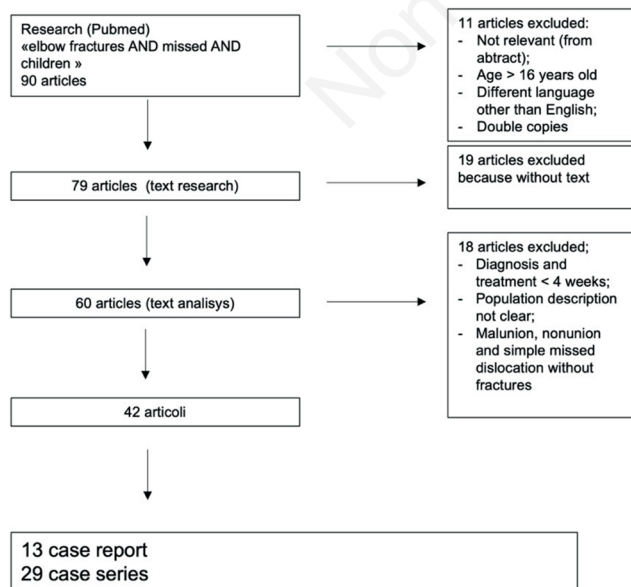


Figure 1. Method of research.

Table 1. Articles selected for the analysis.

Authors	Title	Paper
Shinohara D, Yasuda T, Arai M, Sato K, Arima T, Kanzaki K	A Long-standing Monteggia fracture in a child who underwent bone lengthening and annular ligament reconstruction: a case report.	J Orthop Case Rep. 2019;9(3):30-33
Liao S, Pan J, Lin H, Xu Y, Lu R, Wu J, Zhao M, Chen H, Cai M, Ding X, Zhao J.	A new approach for surgical treatment of chronic Monteggia fracture in children.	Injury 2019 Jun;50(6):1237-1241
Lima S, Correia JF, Ribeiro RP, Martins RM, Alegrete N, Coutinho J, Melo Costa GJ.	A rare case of elbow dislocation associated with unrecognized fracture of medial epicondyle and delayed ulnar neuropathy in pediatric age.	Shoulder Elbow Surg. 2013 mar;22(3):e9-e11
Neves N, Pinto R, Tullha J, Ribeiro da Silva M, Matos R, Trigo-Cabral A.	Chronic post-traumatic lateral dislocation of the radial head.	Orthop Traumatol Surg Res. 2010 Apr;96(2):199-202
Bor N, Rubin G, Rozen N, Herzenberg JE.	Chronic anterior monteggia lesions in children: report of 4 cases treated with closed reduction by ulnar osteotomy and external fixation.	J Pediatr Orthop. 2015 Jan;35(1):7-10
Tallon Lopez J, Vilches Fernandez JM, Dominguez Amador JJ, Flores Ruiz MA.	Chronic incarceration of the medial epicondyle: a case report.	J Shoulder Elbow Surg. 2012 May;21(5):e12-5
Gyr BM, Stevens PM, Smith JT.	Chronic Monteggia fractures in children: outcome after treatment with the Bell-Tawse procedure.	J Pediatr Orthop B. 2004 Nov;13(6):402-6
Rodgers WB, Waters PM, Hall JE.	Chronic Monteggia lesions in children. Complications and results of reconstruction.	J Bone Joint Surg Am. 1996 Sep;78(9):1322-9
Wang MN, Chang WN.	Chronic posttraumatic anterior dislocation of the radial head in children: thirteen cases treated by open reduction, ulnar osteotomy, and annular ligament reconstruction through a Boyd incision.	J Orthop Trauma. 2006 Jan;20(1):1-5
Saraf SK, Tuli SM.	Concomitant medial condyle fracture of the humerus in a childhood posterolateral dislocation of the elbow.	J Orthop Trauma. 1989 3(4):352-354
Lotz B, Akiyama O, Karthik K.	Delayed reconstruction following incarceration of the medial epicondyle in the elbow joint: a case report and review of the literature.	JBJS Case Connect. Jul-Sep 2018;8(3):e69
Datta T, Chatterjee N, Kisor Pal A, Kumar Das S.	Evaluation of outcome of corrective ulnar osteotomy with bone grafting and annular ligament reconstruction in neglected monteggia fracture dislocation in children.	J Clin Diagn Res. 2014 Jun;8(6):LC01-04
Cevi K HB, Yuvaci F, Ecevi Z E, Bulut G.	Four different management strategies in missed Monteggia lesions in children.	J Orthop. 2020 Mar 28;21:207-212
Kumar EGM, Kumar GMY, Noorudheen M.	Functional outcome of Bell Tawse procedure for the management of chronic unreduced Monteggia fracture dislocation in children.	Indian J Orthop. Nov-Dec 2019;53(6):745-750
Rahbek O, Rasmussen Deutch S, Kold S, Sojbjerg JO, Moller-Madsen B.	Long-term outcome after ulnar osteotomy for missed Monteggia fracture dislocation in children.	J Child Orthop. 2011 Dec;5(6):449-57
Deiwani AS.	Missed Monteggia fracture dislocation in children.	Injury. 1997 28(2):131-133
Koslowsky TC, Mader K, Wulke AP, Gausepohl T, Pennig D.	Operative treatment of chronic Monteggia lesion in younger children: a report of three cases.	J Shoulder Elbow Surg. Jan-Feb 2006;15(1):119-21
Ruchelsman D, Pasqualetto M, Price AE, Grossman JAL.	Persistent posterior interosseous nerve palsy associated with a chronic Hand (NY) type I Monteggia fracture-dislocation in a child: a case report and review of the literature.	2009 Jun;4(2):167-72
Delpont M, Jouve JL, Sales de Gauzy J, Louahem D, Vialle R, Bollini G, Accadbled F, Cottalorda J.	Proximal ulnar osteotomy in the treatment of neglected childhood Monteggia lesion.	Orthop Traumatol Surg Res. 2014 Nov;100(7):803-7
Yildirim A, Nas K.	Rehabilitation of neglected Monteggia fracture: dislocation in children.	J Back Musculoskelet Rehabil. 2017 Nov 6;30(6):1251-1257

To be continued on next page

Table 1. Continued from previous page.

Authors	Title	Paper
Take M, Tomori Y, Sawazumi T, Majima T, Nanno M, Takai S.	Ulnar osteotomy and the ilizarov mini-fixator for pediatric chronic monteggia fracture-dislocations.	Medicine (Baltimore) 2019 Jan;98(1):e13978
El-Sobky TA, Haleem JF, Sakr HM, Aly AS.	A neglected markedly displaced medial epicondyle fracture with simultaneous ulnar nerve palsy in an adolescent.	Clin Orthop Surg. 2017 Dec;9(4):542-546
Hafiah NHM, Ibrahim S, Sapuan J, Abdullah S.	An elbow dislocation in a child with missed medial epicondyle fracture and late ulnar nerve palsy.	J Pediatr Orthop B. 2010 Sep;19(5):459-61
Frank JM, Saltzman BM, Garbis N, Cohen MS.	Articular shear injuries of the capitellum in adolescents.	J Shoulder Elbow Surg. 2016 Sep;25(9):1485-90
Fabry J, De Smet L, Fabry G.	Consequences of a fracture through a minimally ossified apophysis of the olecranon.	J Pediatr Orthop B. 2000 Jun;9(3):212-4
Supakul N, Hicks RA, Caltoun CB, Karmazyn B.	Distal humeral epiphyseal separation in young children: an often-missed fracture-radiographic signs and ultrasound confirmatory diagnosis.	AJR Am J Roentgenol. 2015 Feb;204(2):W192-8
Wang Q, Du MM, Pei XJ, Luo JZ, Li YZ, Liu YC, Wang X, Cao JC, Han JH.	External fixator-assisted ulnar osteotomy: a novel technique to treat missed Monteggia fracture in children.	Orthop Surg. 2019 Feb;11(1):102-108
Park H, Park KW, Park KB, Kim HW, Eom NK, Lee DH.	Impact of open reduction on surgical strategies for missed Monteggia fracture in children.	Yonsei Med J. 2017 Jul;58(4):829-836
Song KS, Rammati K, Bae KC, Cho CH, Lee KI, Son ES.	Indirect reduction of the radial head in children with chronic Monteggia lesions.	J Orthop Trauma. 2012 Oct;26(10):597-601
Possey SL, Cole HA, Halverson S, Stutz C, Schoenecker JG.	Intra-articular Monteggia fracture: a case study of using the center of rotational angulation to improve functional outcome.	J Orthop Case rep. Nov-Dec 2018;8(6):27-30
Gaston MS, Irwin GJ, Huntley JS.	Lateral condyle fracture of a child's humerus: the radiographic features may be subtle.	Scott Med J. 2012 Aug;57(3):182
Nakamura K, Hirachi K, Uchiyama S, Takahara M, Minami A, Imaeda T, Kato H.	Long-term clinical and radiographic outcomes after open reduction for missed Monteggia fracture-dislocation in children.	J Bone Joint Surg Am. 2009 Jun;91(6):1394-404
Lu X, Wang YK, Zhang J, Zhu Z, Guo Y, Lu M.	Management of missed Monteggia fractures with ulnar osteotomy, open reduction, and dual-socket external fixation.	J Pediatr Orthop 2013 Jun;33(4):398-402
Eamsobhana P, Chalayon O, Kaewpornsawan K, Ariyawatkul T.	Missed Monteggia fracture dislocations treated by open reduction of the radial head.	Bone Joint J. 2018 Aug;100-B(8):1117-1124
Bhaskar A.	Missed Monteggia fracture in children: is annular ligament reconstruction always required?	Indian J Orthop 2009 Oct-Dec;43(4):389-395
Degreef I, De Smet L.	Missed radial head dislocations in children associated with ulnar deformations: treatment by open reduction and ulnar osteotomy.	J Orthop Trauma 2004 Jul;18(6):375-8
Xu Z, Li Y, Wang Z, Cai H.	Open reduction combined with CORA-based osteotomy of the ulna in the treatment of missed Bado type I Monteggia injury: a retrospective study of 5 cases.	Medicine (Baltimore) 2017 Nov;96(47):e8609
Di Gennaro GL, Martinelli A, Bettuzzi C, Antoniolli D, Rotini R.	Outcomes after surgical treatment of missed Monteggia fractures in children.	Musculoskelet Surg 2015 Sep;99 Suppl 1:S75-82
Lu X, Yan G, Wang Y, Zhu Z, You H, Zhang J, Guo Y.	Repositioning of the annular ligament in the management of missed Monteggia fracture.	J Pediatr Orthop 2017 Jan;37(1):20-22
Rajasekaran S, Venkatadass K.	"Sliding angulation osteotomy": preliminary report of a novel technique of treatment for chronic radial head dislocation following missed Monteggia injuries.	Int Orthop. 2014 Dec;38(12):2519-24
Cottalorda J, Bourelle S.	The often-missed Kocher-Lorenz elbow fracture.	Orthop Traumatol Surg Res. 2009 Nov;95(7):547-50
Chen HY, Wu KW, Dong ZR, Huang SC, Kuo KN, Wang TM.	The treatment of chronic radial head dislocation in Monteggia fracture without annular ligament reconstruction.	Int Orthop 2018 Sep;42(9):2165-2172

Rare complications were stiffness with loss of complete range of motion (4 patients), elbow valgus deviation (2 patients), nascent compartment syndrome (2 patients), heterotopic ossification (2 patients), 1 fibrous synostosis, 1 conversion syndrome that required psychiatric treatment.

Three patients required further surgery more than 5 years later (1 diagnostic arthroscopy of an osteochondral lesion, 1 radial head resection, 1 arthroscopic synovectomy). One patient, in the end, complained about esthetic ulnar prominence at osteotomy site.

Discussion

Despite during years, many authors contributed to the comprehension of Monteggia lesion, it remains a challenge for orthopedics. Analyzing literature, it seems the most common missed elbow lesion in population under 16 years old, with an average age of 6.8 years old and males more affected than female.

There are not clear indications about how to define a lesion as chronic: the articles analyzed that consider lesions after 4 weeks showed an average time of 11.6 months with a wide spectrum (4 weeks-5 years) and there are no clear criteria to define a chronic lesion.

It might be reasonable to think that a temporal criterion cannot be strictly used but may it may be advisable to consider ulnar healing; this parameter, in fact, act as a watershed for the choice of treatment (closed reduction attempts versus ulnar lengthening needing to reduce radial head).

Classifications are another challenge because they seem to be still not comprehensive of other the possible clinical presentations; Bado's is certainly the most spread and used and Type I, in which there is an anterior dislocation of radial head, the most common in pediatric age.¹

In one article Lett's classification⁴ is used: ulnar axis is analyzed on X-rays to check even not displace and incomplete fracture as buckle or bowing or plastic deformation typical of pediatric age. A greater diffusion of this classification may be useful to avoid missing lesion, supporting by clinical examination (Figure 2).

In the majority of cases, limited range of motion and valgus deviation are clinically evident to raise the suspect after a previous trauma; these can lead to perform the X-rays that, in most cases, is enough to make diagnosis.

There is still not consensus about the treatment of missed Monteggia. The debated points are: i) The need for lengthening and flexing the ulna with an osteotomy that led the radial head to relocate; ii) The necessity of an open reduction to clean the radio

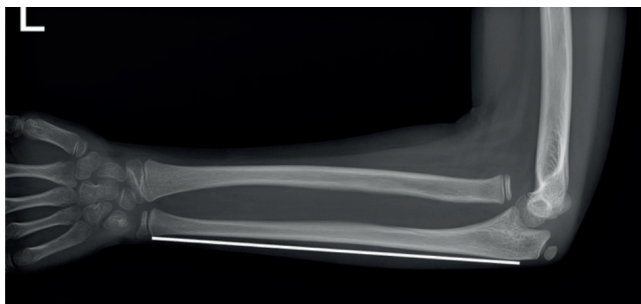


Figure 2. Example of a missed Monteggia Bado I and Letts's A.

humeral joint as well as to check the reduction; iii) The role of a temporary radio humeral joint fixation with Kirschner wire to keep the radial head reduced; iv) The repair/reconstruction of annular ligament; there are fewer certainties, so that in 78 patients was not repaired or reconstructed. For those who advocate reparation, however, this was mostly made according to Bell-Tawse with a tricipital band strip.

In 25% of patients no complications were described and, both in acute and in late setting, the most common one was the loss of reduction of radial head, mostly due to technical error and wrong fixation device and that not always require further surgical treatment.

Conclusions

Even though throughout the years many authors contributed to the comprehension of Monteggia lesion, it remains a challenge for orthopedic surgeons who must deal with; it can lead, if missed, to a chronic condition that can be more difficult to manage in terms of timing and surgery choice. In literature there is no agreement about chronic Monteggia's definition as the timings described are extremely variable and, in the average of studies, the diagnosis is reached months after initial trauma.

A suggestion may be to define as chronic a lesion diagnosed long after the trauma occurred, which cannot be treated as acute anymore but needed a more invasive surgery.

Another point to be discussed is if it may be helpful to consider ulnar fracture healing as a parameter to consider a Monteggia as chronic, due to the fact that fracture consolidation does not allow the surgeons to relocate with external maneuver the radial head.

Classifications are still another grey zone; Letts in association to Bado's classification may be useful in trying to locate those ulnar fractures that can be missed (for examples buckle or plastic deformation).

Even treatment described in literature is extremely variable but the key, in chronic lesion, seems ulnar lengthening to allow radial head relocation. It seems not so mandatory annular ligament treatment, but repair or reconstruction can be performed in case of long-lasting chronic dislocation to give more stability, especially in cases in which radial head surface began to deform with not perfect congruence with capitulum humeri.

Generally, surgery results are favorable although some complications were described. However, the best path to avoid missing a Monteggia's lesion is to always take it into account and to look for a radial head dislocation in every case of a pediatric forearm injury involving the ulna.

References

1. Shah AS, Samora JB. Monteggia Fracture-Dislocation in Children. In Waters PM, Skaggs DL, Flynn JM. Rockwood and Wilkins' Fractures in Children. Ninth Edition. Wolters Kluwer Ed.; Philadelphia: 2020.
2. Monteggia GB. *Instituzioni chirurgiche*. Maspero; Milano: 1814.
3. Bado JL. The Monteggia lesion. *Clin Orthop Relat Res* 1967;50:71-86.
4. Letts M, Loch R, Wiens J. Monteggia fracture-dislocations in children. *J Bone Joint Surg Br* 1985;67:724-7.