

Anterior vertebral body tethering as a treatment for scoliosis in skeletally immature patients

Valentina Caretti, Antonio Andreacchio, Luca Colombo

Pediatric Orthopedics and Traumatology, "Vittore Buzzi" Children's Hospital, Milan, Italy

Abstract

A relatively new surgical procedure called Anterior Vertebral Body Tethering (AVBT) is used to treat scoliosis in patients with immature skeletons. It is a growth modulation fusionless system that Crawford and Lenke first described in 2010. We present our observations from 25 patients.

Correspondence: Valentina Caretti, Pediatric Orthopedics and Traumatology, "Vittore Buzzi" Children's Hospital, Via Castelvetro 32, 20154, Milan, Italy.
E-mail: valentina.caretti@asst-fbf-sacco.it

Key words: Anterior vertebral body tethering; scoliosis.

Funding: None.

Contributions: All authors contributed equally to this article

Conflict of interest: The authors declare no conflict of interest.

Availability of data and materials: All data generated or analyzed during this study are included in this published article.

Ethics approval and consent to participate: The study is conformed with the Helsinki Declaration of 1964, as revised in 2013, concerning human and animal rights. The data was collected retrospectively and no consent was required.

Informed consent: No specific consent is needed for statistical analyses of aggregated deidentified data

Received for publication: 30 September 2022.

Revision received: 4 October 2022.

Accepted for publication: 4 October 2022.

Publisher's note: All claims expressed in this article are solely those of the authors and do not necessarily represent those of their affiliated organizations, or those of the publisher, the editors and the reviewers. Any product that may be evaluated in this article or claim that may be made by its manufacturer is not guaranteed or endorsed by the publisher.

©Copyright: the Author(s), 2022

Licensee PAGEPress, Italy

La Pediatria Medica e Chirurgica 2022; 44(s1):291

doi:10.4081/pmc.2022.291

This work is licensed under a Creative Commons Attribution-NonCommercial 4.0 International License (CC BY-NC 4.0).

Improvement in the mean coronal Cobb angle, from mean 57° preoperative to mean 34° postoperative, was 40%. Additionally, we noted that the mean thoracic hypokyphosis improved from 16° to 24° on average after surgery. Complication rates were 16% and surgical revision rates were 12%. All patients who demonstrated improvement in pain, function, and self-image underwent administration of the SRS-24 questionnaire. These data, according to the literature, show that AVBT is a reliable technique that enables scoliosis correction in skeletally immature patients and maintains that correction while utilizing remaining growth potential to achieve further correction, avoiding spinal fusion, and maintaining spine mobility.

Introduction

Anterior Vertebral Body Tethering (AVBT) is a relatively recent surgical technique for treatment of scoliosis in skeletally immature patients. It is a growth modulation fusionless system based on Hueter-Wolkman principle.¹

AVBT consists in tethering the spine using staples and screws instrumentation placed in the vertebral bodies from the convex side. Each vertebral body is instrumented with one staple and one hydroxyapatite-coated screw placed perpendicularly to the end plates. When all screws are placed a cable (the tether) is inserted in the tulips to connect the screws to each other and then tensioned until tilted end plates are in neutral alignment (if possible) starting from the two most cephalic screws. The tension modifies local forces acting on the vertebrae involved, determining more compression on the convex side of the curve and less compression on the concave side. This change of forces decreases growth rate on convex side and accelerate growth rate on concave side, allowing progression of correction during residual growth in addition to the amount of curve correction obtained during surgery.

AVBT is performed with Video-Assisted Thoracic Surgery (VATS) approach.

This technique aims to avoid spinal fusion and to preserve spine mobility. The first case report was published in 2010 by Crawford and Lenke.² Since then this technique has become more and more popular for treatment of scoliosis in skeletally immature patients.

This study presents our experience with VATS AVBT.

Study presentation

Twenty-five patients have been submitted to VATS AVBT between December 2018 and December 2021 at the same institu-

tion, 21 females and 4 males. Twenty patients were affected by idiopathic scoliosis, 5 were affected by scoliosis secondary to other pathologies (Friedreich ataxia, Arnold-Chiari syndrome, skeletal dysplasia, autism). Mean age at time of surgery was 12 years.

All deformities were classified Lenke 1 A or B, right convexity.

On preoperative x-rays we collected data about coronal Cobb angle and thoracic kyphosis measured between T5 and T12.

Preoperative mean coronal Cobb angle was 57 and mean thoracic kyphosis was 16°.

We also assessed flexibility of the curve, necessary for this kind of surgery, by supine side bending x-rays.

Skeletal maturity was assessed according to Risser and

Sanders stages: for all patients Risser was 0-3 and Sanders 1-5 (Figure 1, Figure 2).

The vertebrae submitted to tethering surgery ranged from D5 to L1 (not all vertebrae were instrumented in every patient depending on the shape of the curve).

Mean time of surgery was 250 minutes. Mean blood loss was <150 cc and no patient required blood transfusion.

Postoperative x-rays were collected immediately after surgery then after 1 month, 3 months, 6 months and then yearly.

Mean follow up was 29 months (range from 6 to 42 months); during this period 13 patients reached skeletal maturity.

Mean coronal Cobb angle at latest radiographs obtained was

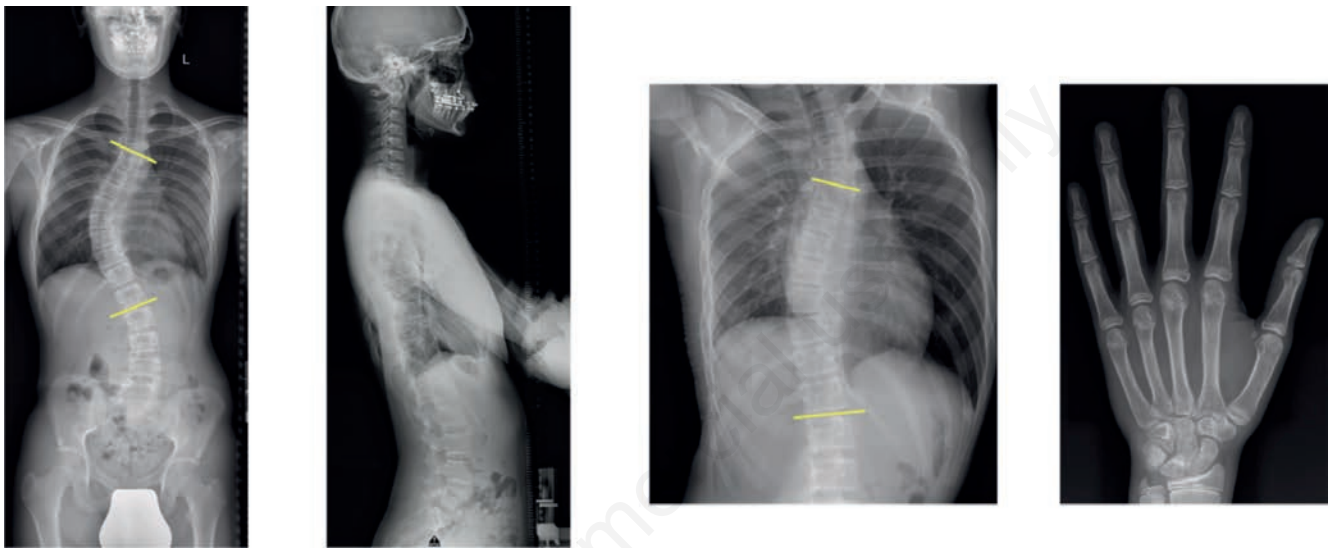


Figure 1. Male, 13 years old. Pre-operative X-rays: thoracic right convex curve Lenke 1B 43° Cobb, 18° on supine side bending, Risser 1, Sanders 3.

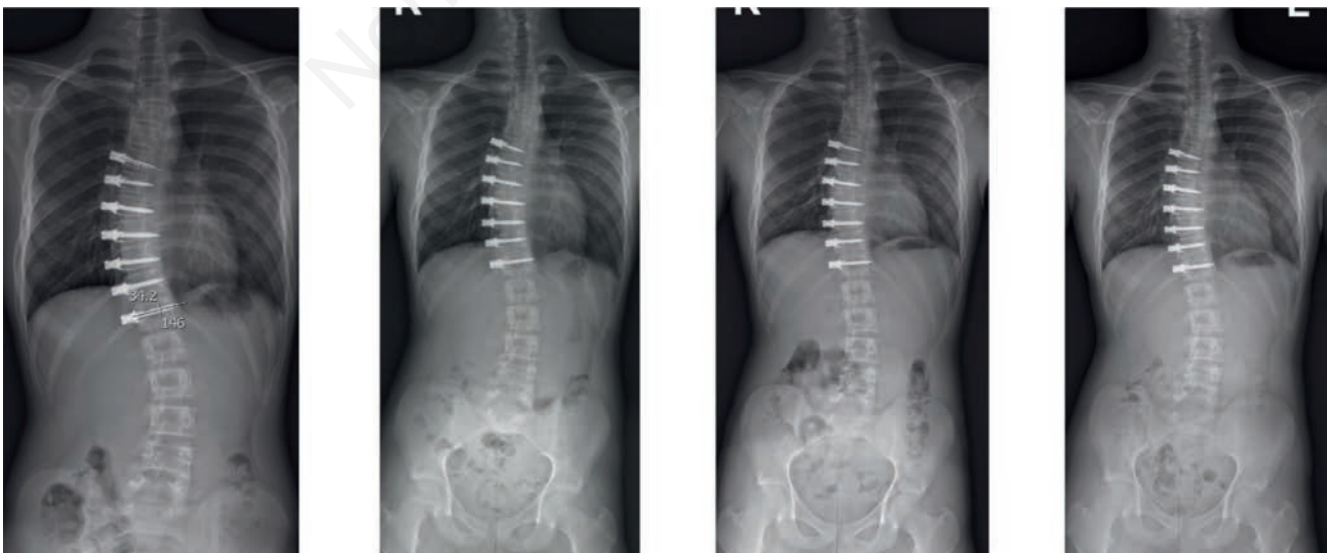


Figure 2. Post-operative X-rays of the same patient in figure 1 showing Cobb angle 24° on postoperative X-rays, 21° six months after surgery, 20° 1 year after surgery and 17° 2 years after surgery.

34° with mean correction of 40%; mean kyphosis turned out to be 24° (Figure 3, Figure 4).

SRS-24 questionnaire was administrated to all patients showing improvement in pain, function and self-image.

Four postoperative complications occurred (16%): i) one case of late postoperative thoracic bleeding (12th postoperative day) that required a second VATS exploration and a chest tube positioning; ii) one case of complete hardware removal due to one long screw touching the aorta in addition to postoperative diagnosis of medullary ependymoma in the same patient; iii) one patient needed a revision of the tether because of lumbar hyper-correction. The tether was cut between the two most caudal

screws; iv) one patient underwent posterior spinal fusion due to distal junctional failure.

All patients returned to their usual daily activity one month after surgery and none of them had to wear a brace.

Discussion

AVBT is a relatively recent surgical technique. Most studies available so far describe quite small group of patients with short-term follow-up. These studies are not always easy to compare due

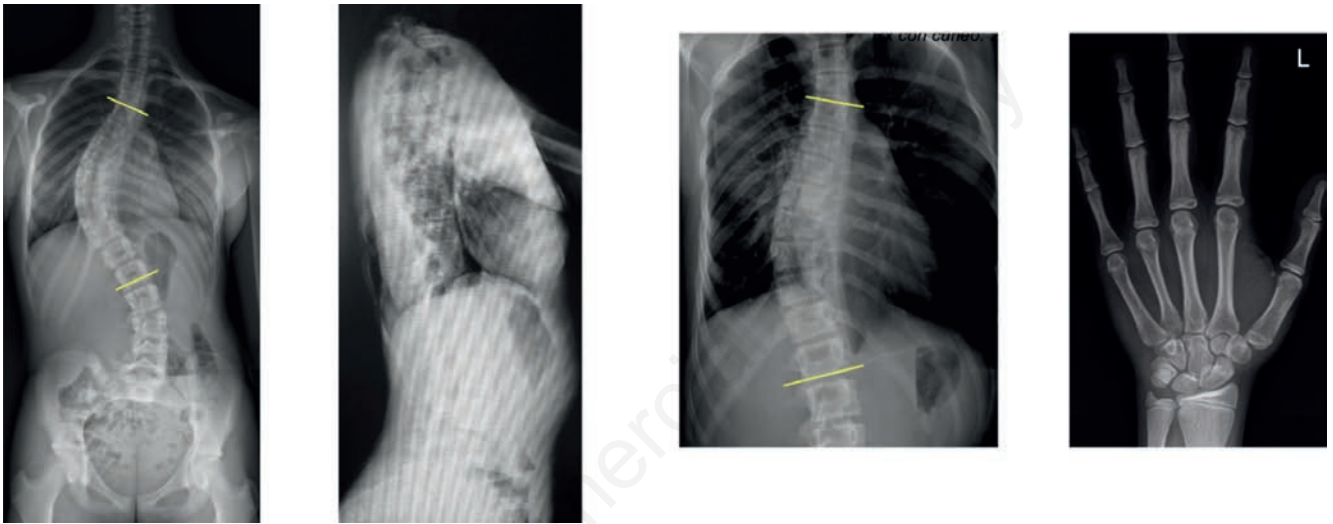


Figure 3. Female, 13 years old. Pre-operative X-rays: thoracic right convex curve Lenke 1A 55° Cobb, Risser 3, 20° Cobb on supine side bending, Risser 3, Sanders 4.

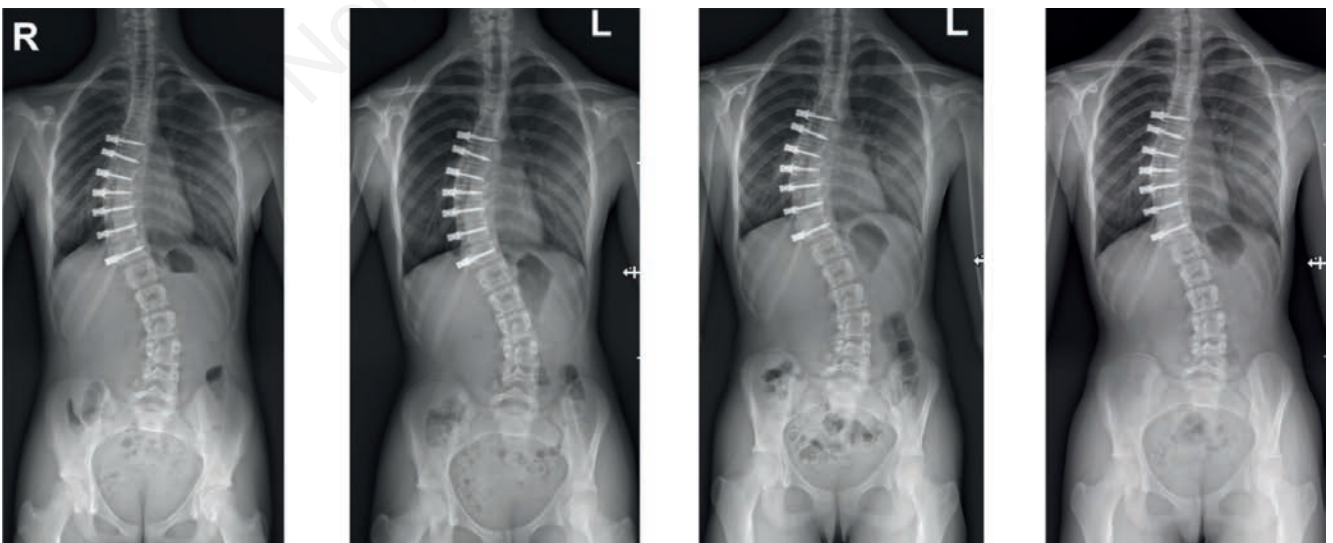


Figure 4. Post-operative X-rays of the same patient in figure showing Cobb angle 32° on postoperative X-rays, 35° six months after surgery, 34° 1 year after surgery and 30° 2 years after surgery.

to differences in patient selection, data collection and definition of “successful” surgery or failure.

In our experience mean coronal Cobb angle improvement was 40%; we also reported thoracic hypokyphosis improvement. The rate of complications was 16% and the rate of revision surgery was 12%.

Rushton *et al.*³ reported reduction of mean Cobb angle from 50.8 + 10.2° before surgery to 25,716,3° at the last follow-up on 112 procedures with a complication rate of 22% and a revision rate of 13%.

Hoernschemeyer *et al.*⁴ reported a rate of successful outcome of 74% on 29 procedures (20 patients with Cobb angle <30° at skeletal maturity) and a revision rate of 21%.

Newton *et al.*⁵ reported their experience on 17 patients with 2 years follow-up, showing mean Cobb angle correction 51% and revision rate 41%.

Samdani *et al.*⁶ reported mean Cobb angle improvement from 40.4° to 18.7° on 57 patients, 80% of curves <30° at the end of follow up and revision rate of 12.3%.

All data available according to our experience indicate that AVBT is a reliable technique that allows to obtain and maintain correction of scoliosis in skeletally immature patients. This technique also allows to exploit residual growth potential to obtain further correction, avoiding spinal fusion and preserving spine mobility.

We want to underline that VATS AVBT requires a multidisciplinary approach and a new learning curve for the entire team.⁷

Conclusions

VATS AVBT is a promising technique for scoliosis treatment in skeletally immature patients.

To date results confirm effectiveness and safety of this kind of

surgery, although further studies on larger population with longer follow-up are needed.

References

1. Stokes IAF. Mechanical effects on skeletal growth. *J Musculoskelet Neuronal Interact* 2002;2:277-80.
2. Crawford CR, Lenke LG. Growth modulation by means of anterior tethering resulting in progressive correction of juvenile idiopathic scoliosis: a case report. *J Bone Joint Surg Am* 2010;92:202-9.
3. Rushton P, Nasto L, Parent S, et al. Anterior vertebral body tethering for treatment of idiopathic scoliosis in the skeletally immature. *Spine* 2021;46:1461-7.
4. Hoernschemeyer DG, Boeyer M, Robertson ME, et al. Anterior vertebral body tethering for adolescent scoliosis with growth remaining: A retrospective review of 2 to 5-year post-operative results. *J Bone Joint Surg Am* 2020;102:1169-76.
5. Newton PO, Kluck DG, Saito W, et al. Bastrom anterior spinal growth tethering for skeletally immature patients with scoliosis: A retrospective look two to four years postoperatively. *J Bone Joint Surg Am* 2018;100:1691-7.
6. Samdani AF, Pahys JM, Ames RJ, et al. Prospective follow-up report on anterior vertebral body tethering for idiopathic scoliosis: Interim results from an FDA IDE study. *J Bone Joint Surg Am* 2021;103:1611-9.
7. Costanzo S, Pansini A, Colombo L, et al. Video-assisted thoracoscopy for vertebral body tethering of juvenile and adolescent idiopathic scoliosis: Tips and tricks of surgical multidisciplinary management. *Children (Basel)* 2022;9:74.