Oculo-auriculo-vertebral spectrum with craniosynostosis and osteo-cartilagineous multiple defects: a diffuse chondro-membranous-osteo-dysplasia

Agostino Berio,[1] Giacomo Garlaschi,[2] Giuseppe Mangiante,[1] Attilia Piazzi[1]

[1]Department of Neurosciences, Rehabilitation, Ophthalmology, Genetics and Mother-Child Sciences, School of Medicine, University of Genoa; [2]Department of Health Sciences, School of Medicine, University of Genoa, Genoa, Italy

Abstract

We report on a female with oculo-auriculo-vertebral spectrum, low height, and on X-ray lambdoid suture synostosis, cerebral cyst/mild holoprosencephalia and cholesteatoma, and multiple abnormalities of bones of chondral origin. On the right side, maxillary, mandibular bones, external auditory canal, middle ear were hypoplastic as well as semicircular canal, cranial base, bones vestibule. On the left side, coclea, timpanic cavity, mastoid antrum were hypoplastic, while stapes was misshapen. Limbs bones were slender with thin metaphyses and some carpal bones were absent. Hand second phalanx was hypoplastic and fifth finger presented clynodactily. Lambdoid synostosis expressed membranous ossification abnormality. We hypothesize that during the blastogenesis a mutation of a factor responsible for abnormal generalized endochondral and connectival ossification (possibly fibroblast growth factor receptor) occurs.

Correspondence: Agostino Berio, Department of Neurosciences, Rehabilitation, Ophthalmology, Genetics and Mother-Child Sciences, School of Medicine, University of Genoa, largo G. Gaslini 5, 16121 Genoa, Italy.
Tel: +39.010.5636248 - Fax: +39.010.3538265.
E-mail: agostinoberio@ospedale-gaslini.ge.it

Contributions: all the authors contributed equally to this work.

Conflict of interest: the authors declare no potential conflict of interest.

Aknowledgements: this paper is dedicated to the memory of Professor R. Bulgarelli, who was always an encouraging stimulus in our scientific work on pediatric bone disease. The authors thank Anna Capurro for her help in revising the manuscript.

Key words: Oculo-auriculo-vertebral spectrum; Lambdoid synostosia; Osteo-cartilaginous defects; Fibroblast growth factor.

Received for publication: 19 August 2015.
Accepted for publication: 24 August 2015.

This work is licensed under a Creative Commons Attribution NonCommercial 3.0 License (CC BY-NC 3.0).

©Copyright A. Berio et al., 2015
Licensee PAGEPress, Italy
La Pediatria Medica e Chirurgica 2015; 37:123
doi:10.4081/pmc.2015.123

Introduction

Oculo-auriculo-vertebral spectrum (OAVS)[1,2] is charachterized by hemifacial hypoplasia, eye, auricular and vertebral defects, and hypoplasia of soft and bony tissues, mainly in the face widespread to many other tissues. The pathogenesis of this condition is complex due to external and genetic causes; many cases are sporadic, but familial instances are also reported. Phenotypes of OAVS are variable and incomplete formsare common.

We report on a patient with OAVS, low height and weight, multiple cerebral malformations, synostosis of lambdoidal suture cartilage, and bone multiple defects demonstrated by X-ray, for which we hypothesized a congenital diffuse chondro-osteodysplasia.

Case Report

The aunt of the proposita presented hemifacial microsomia, bilateral stenosis of external auditory canal, and middle ear cholesteatoma. During gestational age, her mother suffered from anemia, gastritis and colitis, while her father was exposed to toxic agents. It was her mother's first pregnancy. The following pregnancy ended in aborted fetus with multiple anomalies and semilobar holoprosencephaly. The proposita, born at term, presented a birth weight of 1850 g, length was 36.7 cm, head circumference 27.5 cm (all below the third percentile).

Physical examination showed cranio-facial asymmetry, right hemifacial microsomia, brachyplagiocephaly, right parietal bossing, micrognathia, ocular hypotelorism, upslanting palpebral fissures with epicanthus, left exotropia, bilateral malformed ears with narrow right external auditory canal, pigmentation of the retina. Feet and hands were small, with flexion and clynodactily of all fingers; muscular hypotonia and hypotrophy were present. At sonography, heart, liver, spleen, kidney, ureters and bladder were normal. Skull X-ray demonstrated craniosynostosis of coronal and (partial) lambdoid sutures. Computed tomography (CT) scan demonstrated a large area, filled with cerebrospinal fluid, communicating with lateral ventricles in the fronto-parieto-occipital region, a condition confirmed at 1 year of life, when magnetic resonance imaging (MRI) showed partial agenesis of the corpus callosum and a large telencephalic pseudocyst, more developed on the left side, communicating with lateral ventricles and third ventricles. Adhesio interthalamica, falx cerebri, and sinusoid structures were present. Posterior fossa was dysmorphic, asymmetric and small; vermis and cerebellar tonsil hernation in the foramen magnum was demonstrated (Arnold-Chiari malformation). The IV ventricle was subtle and distorted.

Non-commercial use only

At 3 years, the child weighed 6700 g, she was 77 cm long with occipitofrontal circumference of 40 cm. Abnormalities in pronation, supination, and extension of the wrist were present. Skeleton radiography showed cranio-facial asymmetry, thin long bones, slightly reduced vertebral bones, coxa valga, delayed carpal bone age, some coned epiphyses, and hypoplastic second phalanx in both fifth fingers.

At 12 years, odontological examination showed asymmetric, laterally displaced mandible, normal teeth. Carpal radiography demonstrated trapezoid bone and semilunar bone absence, deformity of scaphoid, and absence of the styloid ulnar nucleus. The metaphyses of radius and ulna were subtle (Figure 1). Platybasia with basilar invagination, epistropheus tooth scoliosis were present on MRI. External ear was bilaterally cupped and hypoplastic; stenosis of the auditory canal, otitis media, and cholesteatoma on right were diagnosed at ear, nose and throat examination. Temporal bone CT showed, on the right side, asymmetrical skull base, short and stenotic auditory canal communicating with a large cavity involving middle ear and antrum, filled with gelatinous material and connected with lateral semicircular canal by a labyrinthine fistula. The ossicles were absent. Semicircular canals, vestibule, cochlea, and internal auditory canal were hypoplastic as well as the third part of the facial nerve and the right carotid artery foramen (Figure 2). On the left side, left middle cranial fossa was more developed, petrous pyramid was more caudal than on the right side, mastoid antrum and tympanic cavity were hypoplastic, stapes appeared grossly shaped, incus and malleus were present, labyrinth and cochlea were hypoplastic.

At 22 years, height was 127 cm (<3rd P). Skull X-ray showed cranial deformity with impressive digitations. Thorax was asthenic with dorsal scoliosis, cuboid shaped vertebral bodies, and thin limb bones (Figure 3) were present.

Chromosomes were normal. Comparative genomic hybridization and fluorescence *in situ* hybridation showed microdeletion of chromosome 1:46,XX,del(1)(q21.1). No mutations of chromosomes/genes SHH, SIX 3, TGF, ZIC were present. Karyograms of mother, father, and sister were normal. Growth hormone and endocrinological tests were normal.

Our patient was diagnosed as having OAVS with cerebral cyst/mild holoprosencephaly, cartilage and bone multiple dysplasia, lambdoid synostosis, cholesteatoma (subsequently operated).

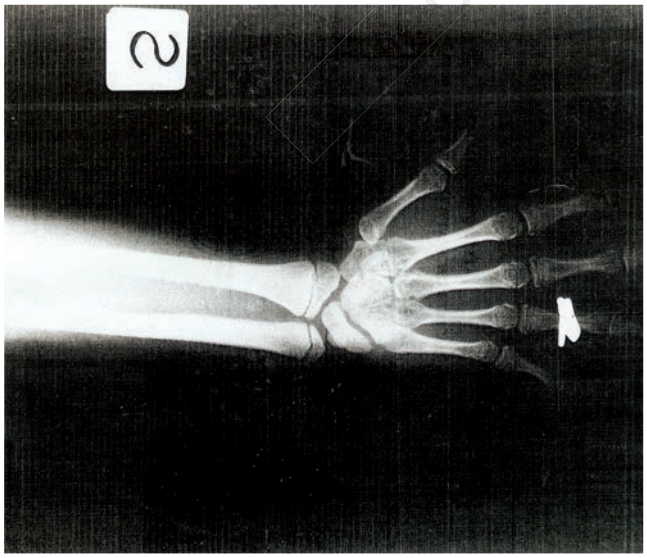

Figure 1. Proposita aged 12 years. Left carpal bones X-rays. Styloid ulnar ossification center, trapezoid and semilunar bones are absent, scaphoid bone is abnormal, metacarpal and phalangeal bones are slender with clynodactily of the fifth finger.

Discussion

The facial cartilages and bones derive from branchial arches, each composed of neural crest cells (NCCs), mesodermal structures, and paraxial mesoderm. The skull calvarial bones derive from connective tissue by direct calcified process. Skull base, vertebral and limb long bones present cartilagineous centers which subsequently ossify.[3,4]

Our patient presented with multiple clinical and radiological skeletal features of face, skull, axial skeleton, limb cartilagineous and osseous tissues with one side prevalence. The cartilage and bone abnormalities were associated with central nervous system (CNS) features. Height was low.

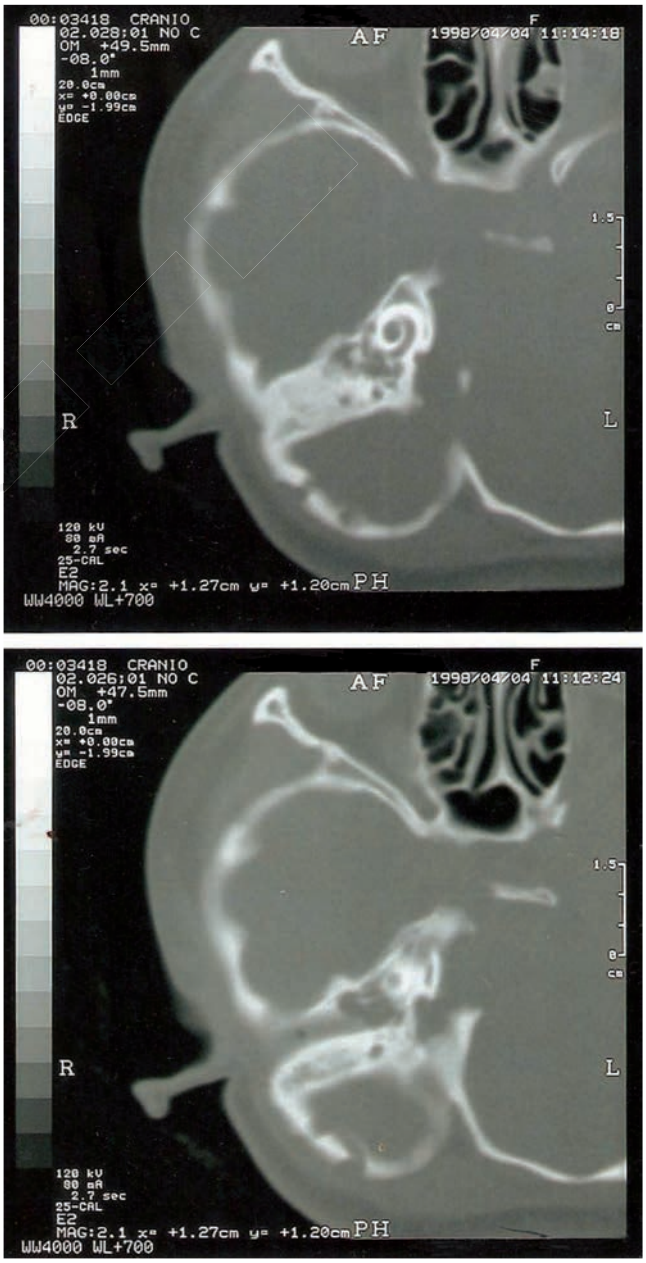

Figure 2. Proposita aged 12 years. Right ear computed tomography scan. Stenotic auditory canal communicating with a large cavity involving middle ear. Ossicles are absent. Hypoplastic inner ear structures.

Radiological examinations demonstrated generalized skeletal hypoplasia and dysplasia of epiphyses, metaphyses, or diaphyses resulting in a disproportionate shortening of limbs or axial skeleton.[5,6] At birth, the following radiological features were present: synostosis of coronal and (partial) lambdoid sutures, platybasia, dysmorphic cerebellar fossa (structures of mesodermal origin), zygomatic hypoplasia and hemifacial microsomia (NCC-derived structures) associated with CNS defects (due to NCC/mesodermal pathological interaction).

Subsequently, epistropheus tooth scoliosis (originating in cartilage before anlagen formation), right middle ear hypoplasia (originating from Meckel's cartilage) with absent ossicles (ascribed to cholesteatoma), and left malformed stapes had relevant radiological features. These anomalies were the expression of interference with facial cartilage development.[3,7] Hypoplasia of the petrous bone and some internal ear structures (semicircular canal, internal auditory canal) were demonstrated by X-ray. Long bones of limbs, thin early in life, presented later on subtle metaphyseal cartilage areas and metacarpal bones, a feature that suggests scarce activity of the cartilage. Absence of some carpal bones and dysmorphic features of others appeared as the direct expression of abnormal chondral development.

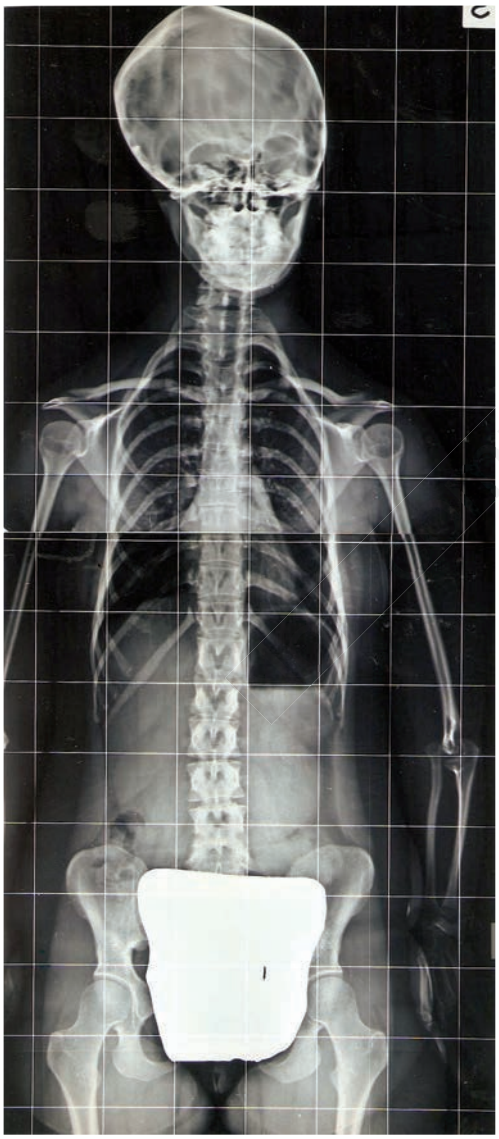

Figure 3. Proposita aged 22 years. Skeletal X-rays: hemifacial microsomia, right parieto-occipital bossing, cuboid-shaped vertebral bodies, dorsal scoliosis, coxa valga, thin limb bones.

Disturbed chondrogenesis is responsible for multiple morphological anomalies of OAVS.[6,7] The pathological process appears early in blastogenesis.[8] The involvement of basicranium (cartilage-derived) is an important mechanism responsible for hemifacial microsomia.[9]

In normal subjects, during brain and anterior bowel development, NCC gives rise to thicknesses as first skull-base structures, which become chondrification centers, subsequently producing the chondrobasi-cranium.[3] Ethmoid, basi-presphenoid, rostrum of parasphenoid, paterigoid bones are NCC-derived, as the anterior part of sella turcica. Postsphenoid, alisphenoid, basi-occipital, exoccipital bones are mesoderm-derived. In our study, all centers were not fused at birth.[3]

The intersphenoideal synchondrosis (separating pre-sphenoid bone from post-sphenoid bone) is completely fused at the third month of post-natal life.[3] In an OAVS patient reported by Goret-Nicaise,[6] the occipital synchondrosis (mesenchyme-derived) appeared hypercalcified only on one side, where bone and chondroid tissue were demonstrated, as in normal fetal skull; on this side, pillars were perpendicular to the endochondral plate and thicker. On the other side, chondral plate was irregular with small cartilagineous pillars, separated from highly mineralized pillars by non-calcified areas. Partial synostosis and morphological anomalies were responsible for basicranial asymmetry.[6] In our case, partial synostosis of the lambdoid suture, demonstrated on X-ray, was possibly responsible of facial asymmetry (as in Goret-Nicaise case).[6] Abnormality of occipital bone (considered a giant vertebra)[3] was responsible for small cerebellar fossa and consequently for Arnold-Chiari malformation.

Neural crest cell-derived facial structures via the formation of 1st and 2nd branchial arches, as the fronto-naso-philtral, maxillary, and mandibular bones, were heavy altered in our patient.

Petrous bone abnormalities with asymmetry suggest mesodermal alterations.[9] Errors in chondrogenesis, due to pathological influences by notochordal and paraxial mesoderm or to a pathological primary mesoderm,[3] should be responsible for the secondary abnormalities in formation, migration and/or differentiation of NCCs,[3] with consequent abnormal development of the first branchial arch[9] (originating Meckel's and palatoquadrate cartilage, mandible, malleus, incus, zygoma, squamous bone, and masticatory muscles) and of the second arch (originating stapes).[9,10] Hemifacial microsomia, microtia, external auditory canal stenosis, and middle ear hypoplasia were ascribed to abnormal skull base cartilage abnormality; the zygomatic arch defect may have occurred secondary to cranial base and sphenoid cartilage abnormality,[7,9] causing a new orientation of temporal bone, and to masseter muscle abnormal attachment.[9]

The right side cavity involving middle ear was ascribed, in our patient, to cholesteatoma, arised in a malformed tympanic cavity with ossicles destruction. Absence of the third part of facial nerve was ascribed to petrous bone hypoplasia and to the semicircular canal hypoplasia.[10,11] The vestibule and cochlea hypoplasia was a sign of otic capsule anomalies.[10,11] All these osseous structures undergo a cartilagineous phase to reach a complete bone structure.[3]

Kay and Kay[9] demonstrated that an interference with cranial base chondrogenesis could be the cause of hemifacial microsomia: in OAVS cranio-facial development, interactions between NCCs and epithelial matrix are relevant in chondrogenesis as well as in osteogenesis; defects in cell differentiation or interaction may be present in the anlagen, leading to abnormal chondro-osteogenesis.[9]

In humans, the neurocranium is divided into cranial base bones,[4,11,12] derived from endochondral ossification, and calvarium, formed of flat bones, which presents an intramembranous ossification.[4,13] The non-neural ectoderm membrane yields the calvarium ectoderm. In mammals, the parietal bone derives from the paraxial mesoderm of rombomeres r2

and r3,[3] the frontal and squamosal bones are NCCs-derived.[3] The first 5 mesodermal somites, during vertebrate evolution, originated the occipital bone: the first somite originated the exoccipital bone; the 2nd, 3rd, 4th and 5th somites yielded the basioccipital, the mesoccipital, and the supraoccipital bones.[3] Calvarium bone tissues are formed by intramembranous ossification, *i.e.* by osteogenetic condensation,[4] a process in which mesenchymal cells stimulated by the activity of bone morphogenetic protein (BMP) and fibroblast growth factor (FGF), proliferate and differentiate into osteoblasts cells, producing (by Cbf 1 or Runx 2) bone matrix and osteoid and forming ossification centers in the primitive membrane which covers the vault.[4] At the margins of the frontal, parietal, temporal, occipital bones, there are sutures connecting different bones. The metopic suture is NCCs-derived. Sagittal, coronal, and lambdoid sutures are mesoderm-derived.[13,14] The sutures are sites of cranial flat bone growth. They initially present proliferation of cells at the margins of the extending bone field (the osteogenic front), then extend and approach or overlap each other with immature fibrous connective tissue interposition[13] and close at different times after birth. When the suture closes prematurely, synostosis is present; lambdoid synostosis presents with fibrous and cartilagineous tissue.[14] Craniosynostoses are heterogeneous: they may be primary, correlate to genetic abnormalities, or secondary, resulting from a know disease.[13] In our case, craniosynostosis of lambdoid suture was present on X-ray at birth, as expression of membranous ossification abnormality.

Vertebral abnormalities, demonstrated by X-ray as small and thin bodies and as epistropheus scoliosis due to a possible endochondral dysplasia, were present in our case. In the axial skeleton (lumbar vertebra) of a patient with OAVS, Goret-Nicaise and colleagues[6] demonstrated by microradiographic and histological methods disturbed endochondral calcification, defects in resorption, abnormal crumpled areas of mineralized cartilage. By methylene blue staining, the radioparent area consisted of uncalcified hyaline cartilage; the less calcified tissue corresponded to bone and the more calcified to normal cartilage, with lesser stained areas corresponding to abnormal cartilage.[6] In our patient, vertebral features similar to Goret-Nicaise and colleagues[6] could be attributed to a primary disturbed chondrogenesis.

In our case, radiologically demonstrated carpal abnormalities were present with bone aplasia (trapezoid, semilunar) or dysplasia (scaphoid) as an expression of endochondral ossification abnormality. Limb bone abnormalities were expressed by slender bone and thin mataphyses, which are also the expression of abnormal endochondral ossification as metacarpal bones. Hypoplasia of phalanges was attributed to mesodermal abnormalities, leading to disorders of endochondral ossification. On the basis of these findings a generalized alteration of chondral ossification was present in our patient, as well as of intramembranous ossification, as signalled by lambdoid craniosynostosis. These features pointed to possible factor(s) causing this chondro-membranous-osteo-dysplasia.

Bone morphogenetic protein and FGF are important growth factors in early development.[8] Members of the FGF family are factors inducing signal transduction in blastogenesis.[8] In native ectoderm, FGF pathway induces mesoderm; when this is formed, gastrulation proceeds to generate the anterior-posterior axis of the embryo. Then, the mesenchyme is transformed into bones by endochondral (skull base and limbs) or intramembraneous (vault) ossification.[8] FGF 2, 4, and 8 are expressed by cells of the apical ectodermal ridge, an area of developing limbs which maintains the cells in a continuous proliferating state.[8,14] Signaling of the FGFs is mediated by FGF receptors (FGFRs).[8] Fibroblast growth factor 1 is expressed in the mesenchyme. Mutation of FGFRs causes alterations of limbs[15] because a lack of signal may induce the maturation of the cells from undiferrentiated to more differentiated mesenchyme. In different embryonic regions, FGF 8, BMP 7, and PAX 1 are demonstrated to be independent from NCCs.[16] In mesenchyme, with NCCs, they constitute a field of functional matrix: when a deficiency of bone is present, this may be due to epithelial program unit deficiency in NCCs or in the biochemistry of epithelial-mesenchymal interaction.[8,14] In branchial arches, FGF8 causes expression of PAX1, BMX, Goosecoid, and endothelin.[16]

Fibroblast growth factors play a role in the complex regulation of suture fusion.[8,14] Together with FGFR, they stimulate the proliferation and prevent the differentiation of osteoblasts, with consequent cranial suture maintenance. At higher signal intensity, FGF and FGFR cause the suture differentiation and closure.[15] Fibroblast growth factor induces FGFR via mitogen expression protein (MEK) and mitogen activated protein kinase (MAP-kinase),[8] and expression of SOX 9[4] induces parathyroid hormone-related protein (PTHrP), which modulates the rate of chondrocyte differentiation.[17] Fibroblast growth factor receptors mutations are associated with gene function abnormality, creating or destroying cysteine residuum, a process activating the receptor with signal function independent of the ligand,[15] resulting at cranial level in precocious fusion of the suture by a gain of function mechanism.[15] Mutations of FGFR are demonstrated in some syndromes associated with craniosynostosis. In Crouzon syndrome, with or without mild hand involvement, the craniosynostosis is due to FGFR 2 mutation; in Apert and in Pfeiffer syndromes (with limbs defects), there are mutations in FGFR 2 and FGFR 1 or FGFR 2, respectively, while in Muencke syndrome, FGFR 3 mutations are present.[15]

In cranio-facial mutant zebrafish (Danio rerio), mutation of fgfr 1, fgfr 2, fgfr 3 cause phenotypes with craniosynostoses, bone length reduction due to chondral bone formation defect, normal teeth, kinked or malformed cartilage, reduced number of chondrocytes, diminished Alcian bleu cartilage staining (hammerhead class).[18] This zebrafish mutant is similar to human syndromes included in the group of FGFR mutations, which present reduced bone length, but not always bone shape alteration and premature suture fusion (Pfeiffer-Crouzon syndromes, achondroplasia).[18]

On the basis of these observations, we may hypothesize a role of FGF/FGFR abnormality also in our case.

Conclusions

The symptomatology present in an aunt of our patient suggests a genetic disease with dominant transmission. The gene(s) responsible of OAVS is (are) unknown, but the mutation present in chromosome 1 may have some relevance: Stahl-Maug reported a pericentric inversion of this chromosome in OAVS.[19]

On the basis of clinical and radiological features present in our case and the histological and biological data of the literature[2,4,6,7] we hypothesize that our OAVS patient presented a vault membranous ossification disease and a generalized disease of the cartilage with a disturbed chondral proliferation, mainly at metaphyseal level, leading to ossification abnormalities of limbs, vertebrae, cranial base, occipital bone, and short stature as well as temporal bone and ear abnormalities. The coexistence of CNS malformations may be ascribed to neural crest derived abnormalities[20] as well as facial abnormality.

The radiological features of skull and limbs, similar to those present in Crouzon and Pfeiffer syndromes due to FGFR mutation, the lambdoid craniosynostosis associated with length reduction, as reported in zebrafish with fgfr mutation, pointed to a possible pathogenetic relevance of FGF/FGFR pathway alteration as the cause of the cartilage abnormality.

In our case, an unknown genetic factor, connected with FGF/FGFR pathway, could be responsible for the chondral and membranous disorder aging before cartilage formation (at gastrulation) and could cause generalized chondro-membranous dysplasia and subsequent osteodysplasia with short height.

References

1. Gorlin RJ, Cohen MM, Lewin LS. Syndromes of the head and neck. Oxford, UK: Oxford University Press; 1990.
2. Berio A, Mangiante G, Oliaro A, Piazzi A. Oculoauriculovertebral spectrum (OAVS) with large cerebral cyst: affinity to holoprosencephaly. Minerva Pediatr 2012;64:549-55.
3. Couly G, Coltey PM, Le Douarin NM. The triple origin of skull in higher vertebrates: a study in quail-chick chimeras. Development 1993;117:409-29.
4. Horton WA. Skeletal development: insights from targeting the mouse genome. Lancet 2003;362:560-8.
5. Hall BD. Approach to skeletal dysplasia. Pediatr Clin N Am 1992;39: 279-305.
6. Goret-Nicaise M, Baertz G, Saussoy BG, Dhem A. Oculo-auriculo-vertebral spectrum: cranial and vertebral malformations due to focal disturbed chondrogenesis. J Craniofac Genet Dev Biol 1997;17:35-47.
7. Cousley RRJ, Wilson DJ. Hemifacial microsomia: developmental consequence of perturbation of the auriculofacial cartilage model? Am J Med Gen 1992;42:461-2.
8. Opitz JM, Zanni G, Reynolds J, Gilbert-Barness E. Defects of blastogenesis. Am J Med Genet 2002;115:269-86.
9. Kay ED, Kay CN. Dysmorphogenesis of the mandible, zygoma and middle ear ossicles in hemifacial microsomia and mandibulofacial dysostosis. Am J Med Genet 1989;32:27-32.
10. Bisdas S, Lenarz M, Lenarz T, Becker H. Inner ear abnormalities in patients with Goldenhar syndrome. Otol Neurotol 2005;26:398-404.
11. Wells MA, Phelps PD, Michaels L. Oculoauriculovertebral dysplasia. J Laryngol Otol 1983;97:689-96.
12. Phelps PD, Lloyd GA, Postvillo DE. The ear deformities in craniofacial microsomia and OAVS dysplasia. J Laryngol Otol 1983;97:995-1005.
13. Cohen MM. Sutural biology and the correlates of craniosynostosis. Am J Med Gen 1993;47:581-616.
14. Cohen M. Malformations of the craniofacial region. Evolutionary, embryonic, genetic, and clinical perspectives. Am J Med Genet 2002;115:245-68.
15. Muenke M, Wilkie A. Craniosynostosis syndromes. In: Scriver RC, Baudet AL, Sly WS, Valle D, eds. The metabolic and molecular bases of inherited disease. New York, NY: McGraw-Hill; 2001. pp. 6117-46.
16. Trump A, Depew MY, Rubenstein JLR, et al. Cre-mediated gene inactivation demonstrates that FGF8 is required for cell survival and patterning of the first branchial arch. Gene Dev 1999;13:3136-48.
17. Vortkamp A, Lee K, Lanske B, et al. Regulation of rate of cartilage differentiation by Indian hedgehog and PTH related protein. Science 1996;273:613-22.
18. Yelick PC, Schilling T. Molecular dissection of craniofacial development using zebrafish. Crit Rev Oral Biol M 2002;13:308-22.
19. Stahl-Maug C, Weiss-Wichert P. Familial pericentric inversion of chromosome 1 in a boy with Goldenhar's syndrome. Hum Genet 1982;61:78.
20. Berio A, Piazzi A. Complesse malformazioni cerebrali (aplasia del Corpo Calloso, cisti prosencefalica), del canale carotico interno e facciali da alterazione delle creste neurali associate a colesteatoma (operato). Minerva Pediatr 2007;59:403-8.

Non-commercial use only